



(RESEARCH ARTICLE)



Crassocephalum rubens extract and fractions: Hypolipidemic and cardioprotective activities

Opeyemi Oluwayemisi Ayodele ^{1,*}, Tamunosabibam Charles Banigo ¹, Emeka Emea Okoro ¹ and Opeyemi Owolabi Ojo ²

¹ Department of Biological Sciences, College of Basic and Applied Sciences, Mountain Top University, Nigeria.

² Department of Chemical Sciences, College of Basic and Applied Sciences, Mountain Top University, Nigeria.

GSC Biological and Pharmaceutical Sciences, 2022, 20(01), 253–261

Publication history: Received on 20 May 2022; revised on 16 July 2022; accepted on 18 July 2022

Article DOI: <https://doi.org/10.30574/gscbps.2022.20.1.0252>

Abstract

Globally, cardiovascular diseases are becoming the major cause of death. *Crassocephalum rubens* is an indigenous vegetable used traditionally in the treatment of several disease conditions including stomach upset, wounds, and high blood pressure. However, there are limited literature reports on its hypolipidemic and cardioprotective activities, hence this study investigated the effects of leaf methanol extract and fractions of *C. rubens* on lipid profile, liver, cardiac marker enzymes; alanine (ALT), and aspartate (AST) aminotransferases, and cardiac tissue integrity in Isoproterenol-induced myocardial infarction (MI) in rats. Forty-five male Wistar rats were randomly divided into nine groups and administered different doses (100 & 150 mg/kg) of the plant extract and fractions for 14 days while normal control and MI control received phosphate buffer saline. *C. rubens* leaf methanol extract and fractions significantly ($p < 0.05$) reduced TC ($75.45 \pm 2.44 - 96.09 \pm 1.65$ mg/dL), TG ($84.04 \pm 1.79 - 127.00 \pm 0.47$ mg/dL), VLDL-C ($16.81 \pm 0.36 - 25.42 \pm 0.10$ mg/dL), LDL-Cholesterol ($03.49 \pm 1.03 - 26.04 \pm 1.64$ mg/dL), and AST of the pretreated myocardial infarcted rats versus MI control (168.70 ± 9.85 mg/dL, 146.60 ± 1.74 mg/dL, 29.31 ± 0.34 mg/dL, 77.73 ± 9.67 mg/dL, respectively), while plasma HDL-C was increased. The crude extract and fractions of *C. rubens* showed significant cardioprotective activities on the integrity of the heart tissues of the experimental rats. The findings reveal antihyperlipidemic and cardioprotective potentials and provide a possible lead for isolation of bioactive compounds from *C. rubens* in the management of hyperlipidemia and its associated ailments.

Keywords: *Crassocephalum rubens*; Histopathology; Isoproterenol; Lipid Profile; Myocardial infarction

1. Introduction

Cardiovascular and its associated diseases (CVDs) rank top among the world-leading causes of death with an estimated global mortality rate of 31% [1-2]. In recent years, the prevalence of CVDs is alarmingly on the increase [3], leading to significant advancement in both diagnostics and therapy [4], with a wide range of drug classes such as anticoagulants, beta-blockers, angiotensin transforming enzyme inhibitors, and angiotensin receptor blockers, among others [5]. However, most of these antihyperlipidemic and hypolipidemic agents pose some side effects.

There are several factors (e.g., smoking, drinking, diabetes, obesity, etc.) indicated in the pathogenesis of myocardial infarction (MI) and cardiovascular diseases. However, dyslipidemia has been reported as one of the most crucial factors in the development of MI [6-7]. Hyperlipidemia is characterized by high levels of blood cholesterol (TC), low-density lipoprotein cholesterol (LDL-C), very low density lipoprotein cholesterol (VLDL-C), and triglycerides (TG). These parameters are the diagnostic markers used in the evaluation of the risk of heart disease [8]. Studies have indicated that increased blood concentrations of TC, TG, LDL-C, VLDL-C, and decreased high-density lipoprotein cholesterol (HDL-C)

* Corresponding author: Opeyemi O Ayodele

Department of Biological Sciences, College of Basic and Applied Sciences, Mountain Top University, Nigeria.

accelerate the development of atherosclerosis and cardiovascular conditions [9-11]. Patients with cardiovascular conditions and hyperlipidemia are usually administered lipid-lowering drugs to reduce the risk of atherosclerotic injury, however, most are accompanied with negative effects such as liver destruction, myopathy, and prospective drug interaction, as in the case with statins [6,12].

Traditional and complementary medicine has grown in popularity in recent years for the treatment of various diseases because of the low toxicity of herbal medicines. Most treatments depend on extracts and active compounds from medicinal plants. Owing to myriads of reported biological activities of medicinal plants, there has been increased interest in the research and application of plants to the management and treatment of a wide range of diseases, including CVDs [13-14].

Crassocephalum rubens [Juss. ex Jacq.] S. Moore is a traditional leafy vegetable that is used to treat some ailments and manage symptoms such as stomach upset, indigestion, headaches, ulcer, swollen lips, etc., in several parts of Africa. *C. rubens* is a perennial shrub belonging to the Asteraceae family. It is predominantly used as a vegetable in salads and sauces in various parts of Africa [15]. The plant is reported to be effective in the treatment and management of disorders like diabetes, inflammation, wounds, liver issues, and sexually transmitted diseases [16-18]. Bioactive compounds such as alkaloids, flavonoids, coumarins, and tannins, have been isolated and characterized from *C. rubens*. The plant was reported to possess antioxidant anti-inflammatory properties [19-20]. Abdominal discomfort, pain, malaria, wounds, and epilepsy are among the diseases that have been reported to be controlled by *C. rubens* traditionally in Nigeria [15]. The study thus investigates the effect of *C. rubens* leaf extract and solvent fractions in a myocardial infarction rat model in a bid to scientifically validate the ethnopharmacological claim as we provide a lead of the plant as a potential source of pharmacological agent for the treatment and management of myocardial infarction and other CVDs.

2. Material and methods

2.1. Plant Material

Aerial parts of *C. rubens* were obtained in April 2021, were obtained from local farms in Ekiti state, Southwestern, Nigeria (between latitude 7.667° N and longitude 5.250° E). The plant was identified at the herbarium of the Department of Botany, University of Lagos, Nigeria, and a voucher specimen (8788) was deposited.

2.2. Plant Preparation and Extraction

The leaves were dried in a hot air oven at 40 °C and pulverized to a fine powder using a laboratory blender, stored in an airtight glass container, and kept refrigerated at 4 °C until further use. Pulverized *C. rubens* (519 g) was soaked in 4,160 mL of 70% methanol (1:8 w/v) and allowed to macerate for 72 h with intermittent shaking.

The filtrate was concentrated at 45 °C in a rotary evaporator and concentrated to dryness in a hot air oven at 40 °C under reduced pressure to obtain the crude extract (71.91 g).

2.3. Solvent fractionation

Following reconstitution of the crude methanolic extract in distilled water in the ratio of 1:5, successive solvent-solvent extraction was carried out to obtain n-hexane (9.48 g), and ethyl acetate (4.3 g) extracts. The extracts were concentrated using a rotary evaporator at 40 °C under reduced pressure and a controlled temperature of 40 °C and stored in the refrigerator at 4 °C.

2.4. Experimental animals

Forty-five albino rats (Wistar strains); 100-220 g were obtained and housed in a standard polypropylene cage in the animal facility of the Department of Biological Sciences, Mountain Top University, Nigeria. The rats were kept in well-ventilated cages in a controlled laboratory environment at room temperature with a 12-hour light/dark cycle and allowed free access to standard rodent pellets and clean water. The Institutional Animal Ethics Committee's ethical requirements for the care and use of laboratory animals (IAEC) were strictly followed during all the experiments, and approval was obtained from the health research ethics committee, College of Medicine, University of Lagos, Nigeria (Approval number: CMUL/ACUREC/09/21/926). The animals were allowed to acclimatize for two weeks. The rats were randomly allocated into 9 experimental groups of 5 animals each as follows:

- Group 1: Normal control (1ml phosphate-buffered saline (PBS)).
- Group 2: Positive control (ISO + Aspirin (75 mg/kg))

- Group 3: Negative control (ISO without pretreatment).
- Group 4: ISO + pretreatment with crude hydromethanol extract of *C. rubens* (100 mg/kg).
- Group 5: ISO + pretreatment with crude hydromethanol extract of *C. rubens* (150 mg/kg).
- Group 6: ISO + pretreatment with hexane fraction of *C. rubens* (100 mg/kg).
- Group 7: ISO + pretreatment with hexane fraction of *C. rubens* (150 mg/kg).
- Group 8: ISO + pretreatment with ethyl acetate fraction of *C. rubens* (100 mg/kg).
- Group 9: ISO + pretreatment with ethyl acetate fraction of *C. rubens* (150 mg/kg).

Pretreatment of animals with plant extract and fractions was done orally daily for 14 days. Myocardial infarction was induced in the rats on day 15. The weights of the rats were taken on days 1, and 16.

2.5. Induction of Myocardial Infarction

Myocardial infarction was induced by a single intraperitoneal injection of isoproterenol (ISO; 100 mg/kg body weight) in phosphate buffer (pH 7.4) [21]. Induction was carried out on day 15, after fasting the rats overnight. The rats were sacrificed under anesthesia on day 16. Blood and organ samples were collected and processed for assays.

2.6. Sample collection and Preparation of Plasma and Tissues

The rats were anesthetized, and blood was obtained through cardiac puncture of the animals into heparinized tubes on the final day of treatment. The liver tissues were excised, weighed, and washed free of blood in normal saline and blotted with tissue paper for the preparation of homogenate. They were homogenized using a mechanical method. The tissue homogenate was centrifuged for 10 minutes at 12000 rpm. Using a bench centrifuge, blood samples were centrifuged for 15 minutes at 2500 rpm to produce plasma.

2.7. Biochemical Studies

2.7.1. Lipid Profile Assay

The plasma total cholesterol (TC), Triglycerides (TAG), and High-density lipoprotein cholesterol (HDL-cho) concentrations were determined using available commercial kits by Randox Laboratories limited, UK. The low-density lipoprotein cholesterol (LDL-cho) and very-low-density lipoprotein cholesterol (VLDL-cho) concentrations were estimated following the instructions on the kits' manual as follows:

$$[\text{LDL-cho}] = [\text{Total cho}] - [\text{HDL-cho}] - [\text{TG}]/5$$

$$[\text{VLDL-cho}] = \text{TG}/5$$

2.7.2. Atherogenic index of the plasma (AIP)

The AIP was calculated using the formula reported by Nwagha, et al. [22].

$$\text{AIP} = \log_{10} (\text{TG}/\text{HDL - cho})$$

2.7.3. Determination of the liver Alanine transaminase (ALT) and Aspartate transaminase (AST) activities

Using assay kits from Randox laboratories, UK, the activity of ALT and AST in the liver of experimental rats was determined following the instructions in the manufacturer's kit insert.

2.8. Histopathological examination

The heart tissues were fixed in 10% formalin, processed, and embedded in paraffin according to the standard method [23]. Sections of 5 μm thickness were cut, deparaffinized, dehydrated, and stained with hematoxylin and eosin (H&E) for the evaluation of pathological changes in the heart under a light microscope. Photomicrographs were taken using a microscope digital camera.

2.9. Statistical Analysis

All data are presented as mean \pm standard error of the mean (SEM). Graph Pad Prism Software (GPPS 9.2) was used to assess variation within a collection of data using a one-way analysis of variance (ANOVA). Statistical significance was defined as a value of $p < 0.05$.

3. Results

3.1. Change in weight and the organ-body ratio of experimental rats

There were no significant differences ($p > 0.05$) in the organ-body ratio (for the heart and liver) of plant-treated rats compared to the MI and normal control groups (Table 1).

Table 1 Body, liver, and heart weights of experimental rats

Groups	Initial body weight (g)	Final body weight (g)	% Change in body weight	Weight of heart(g)	Heart/body ratio (%)	Weight of liver(g)	Liver/body ratio (%)
Normal control	142.00 ± 12.31	154.00 ± 12.15	8.45 ± 1.30	0.52 ± 0.03	0.34 ± 0.04	1.14 ± 0.21	0.74 ± 0.02
MI control	217.00 ± 13.17	170.00 ± 11.88	27.65 ± 8.86 ^{^^}	0.70 ± 0.04	0.41 ± 0.14	2.12 ± 0.26	1.25 ± 0.02
MI + Aspirin (75 mg/kg)	174.00 ± 13.29	184.00 ± 18.32	5.43 ± 0.27	0.75 ± 0.07	0.41 ± 0.08 ^{ns}	1.81 ± 0.19	0.98 ± 0.01 ^{ns}
MI + ME (100 mg/kg)	149.00 ± 12.83	172.00 ± 11.41	15.44 ± 9.07	0.63 ± 0.04	0.37 ± 0.11 ^{ns}	1.77 ± 0.19	1.02 ± 0.14 ^{ns}
MI + ME (150 mg/kg)	135.00 ± 1.11	166.00 ± 6.54	18.67 ± 4.89	0.65 ± 0.04	0.38 ± 0.04 ^{ns}	1.73 ± 0.16	1.04 ± 0.12 ^{ns}
MI + HF (100 mg/kg)	155.00 ± 12.88	169.00 ± 14.94	9.03 ± 0.16	0.76 ± 0.04	0.45 ± 0.02 ^{ns}	1.13 ± 0.09	0.67 ± 0.09 ^{ns}
MI + HF (150 mg/kg)	155.00 ± 9.57	180.00 ± 16.50	16.13 ± 0.72	0.75 ± 0.08	0.42 ± 0.14 ^{ns}	1.00 ± 0.15	0.56 ± 0.02 ^{ns}
MI + EF (100 mg/kg)	115.00 ± 2.07	156.00 ± 12.37	26.28 ± 0.83 ^{^^}	0.73 ± 0.06	0.47 ± 0.19 ^{ns}	2.31 ± 0.09	1.48 ± 0.02 [^]
MI + EF (150 mg/kg)	102.00 ± 3.81	146.00 ± 7.36	30.14 ± 0.48 ^{^^}	0.70 ± 0.04	0.48 ± 0.04 ^{ns}	1.64 ± 0.08	1.12 ± 0.04 ^{ns}

Values were expressed as mean ± SEM (n=5). Values were statistically significant at [^]p<0.05, ^{^^}p<0.01, ns; not significant, vs Normal control as analyzed by one-way ANOVA followed by Tukey's multiple comparison test. MI: myocardial infarction, ME: methanol extract, HF: hexane fraction. EF: ethyl acetate fraction; % Change in body weight = change in body weight/Initial body weight X 100; % Organ/body ratio = weight of organ /final body weight X 100

3.2. Effects of *C. rubens* extract on the lipid profile and atherogenic index of plasma

The values of the plasma TC, TG, LDL-chol, and VLDL-chol ((168.70 ± 9.85, 146.60 ± 1.74, 29.31 ± 0.34, 77.73 ± 9.67, and 41.66 ± 0.29 mg/dL, respectively) were higher in MI control group when compared with the normal control group (129.90 ± 3.57, 141.80 ± 0.55, 28.36 ± 0.11, 46.47 ± 3.81, and 35.07 ± 0.74 mg/dL, respectively). The values recorded in the pretreated groups were significantly ($p < 0.05$) lower compared with the MI control. The HDL-chol concentration was significantly increased with both concentrations of ME and EF (Table 2). The AIP is significantly reduced in the treatment groups compared with the MI control group (0.55 ± 0.01), with the lowest value (0.18 ± 0.0) recorded in the group pretreated with ME (100 mg/kg).

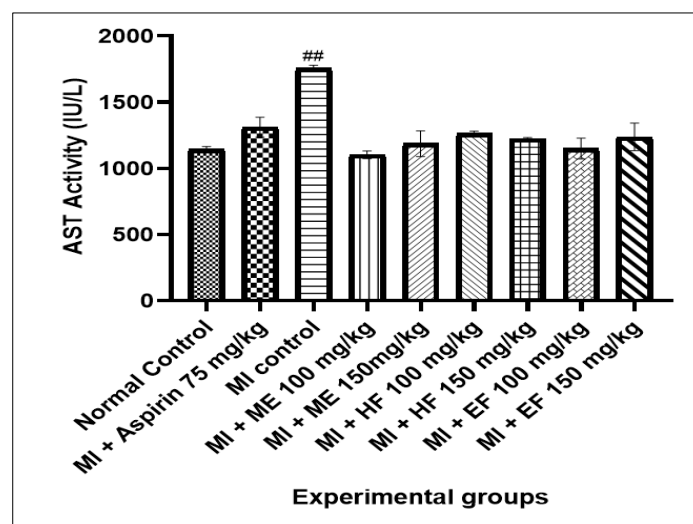
3.3. ALT and AST activities in the experimental rats

The liver AST activity was significantly higher ($p < 0.05$) in the MI control group compared with the normal control and the plant-treated groups. However, there are no differences in the values recorded among the treatment groups and the normal control (Fig. 1). There was no difference in the ALT activity among the experimental groups, except for EF (100 mg/kg) in which a significant increase was recorded (Fig. 2).

Table 2 Effect of *C. rubens* leaf extract and fractions on Plasma lipid profile of Myocardiatic rats

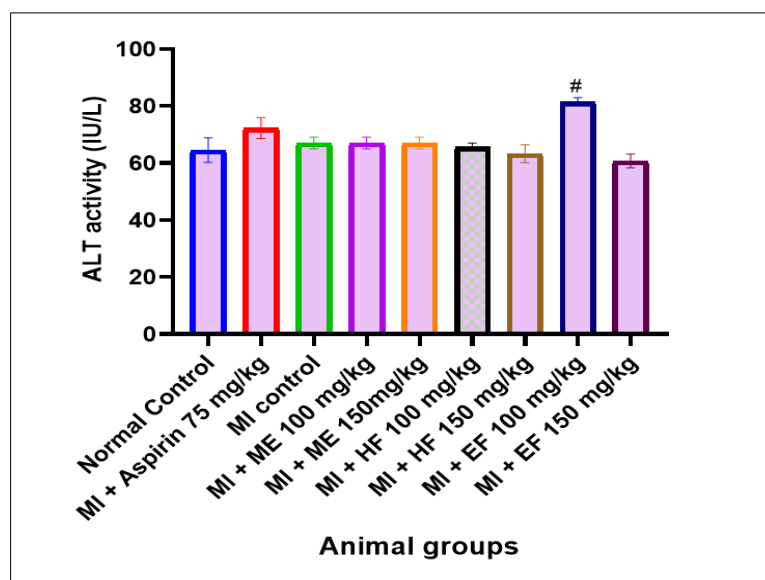
Parameters Group	TC mg/dL	TG mg/dL	VLDL-chol mg/dL	LDL-chol mg/dL	HDL-chol mg/dL	AIP
Normal control	129.90 ± 3.57**	141.80 ± 0.55	28.36 ± 0.11	46.47 ± 3.81**	35.07 ± 0.74*	0.61 ± 0.01
MI control	168.70 ± 9.85	146.60 ± 1.74	29.31 ± 0.34	77.73 ± 9.67	41.66 ± 0.29	0.55 ± 0.01
MI + Aspirin (75 mg/kg)	115.65 ± 14.76**	130.20 ± 1.17**	26.04 ± 0.23**	25.18 ± 3.54***	44.43 ± 2.41	0.47 ± 0.03**
MI + ME (100 mg/kg)	79.28 ± 3.97***	91.84 ± 1.09***	18.37 ± 0.22**	07.32 ± 2.62***	51.42 ± 0.47**	0.25 ± 0.01***
MI + ME (150 mg/kg)	75.45 ± 2.44***	84.04 ± 1.79***	16.81 ± 0.36**	03.49 ± 1.03***	55.15 ± 0.52**	0.18 ± 0.01***
MI + HF (100 mg/kg)	96.09 ± 1.65***	127.00 ± 0.47***	25.42 ± 0.10**	26.04 ± 1.64***	44.63 ± 0.46	0.45 ± 0.01**
MI + HF (150 mg/kg)	84.60 ± 4.69***	119.40 ± 1.21***	23.88 ± 0.24**	18.11 ± 2.67***	42.61 ± 0.35	0.45 ± 0.01**
MI + EF (100 mg/kg)	82.15 ± 1.46***	105.50 ± 0.94***	21.09 ± 0.38**	12.28 ± 1.85***	48.78 ± 0.03**	0.34 ± 0.01**
MI + EF (150 mg/kg)	79.20 ± 4.03***	102.90 ± 0.67***	20.58 ± 0.13**	09.93 ± 1.72***	48.69 ± 0.95**	0.33 ± 0.01**

Values were expressed as mean ± SEM (n=5). Values were statistically significant at * $p < 0.05$, ** $p < 0.01$, *** $P < 0.001$ vs MI control as analyzed by one-way ANOVA followed by Tukey's multiple comparison test; TC: Total cholesterol, TG: Triglycerides, VLDL-chol: very low-density lipoprotein cholesterol, LDL-chol: Low-density lipoprotein cholesterol, HDL-chol: High-density lipoprotein cholesterol, AIP: atherogenic index of plasma, MI: myocardial infarction, ME: methanol extract, HF: hexane fraction. Ef: ethyl acetate fraction.



Values were expressed as mean ± SEM (n=5). Values were statistically significant at ^{##} $p < 0.01$ vs Normal control as analyzed by one-way ANOVA followed by Tukey's multiple comparison test. MI: myocardial infarction, ME: methanol extract, HF: hexane fraction. EF: ethyl acetate fraction

Figure 1 Aspartate transaminase activity in the liver of experimental rats

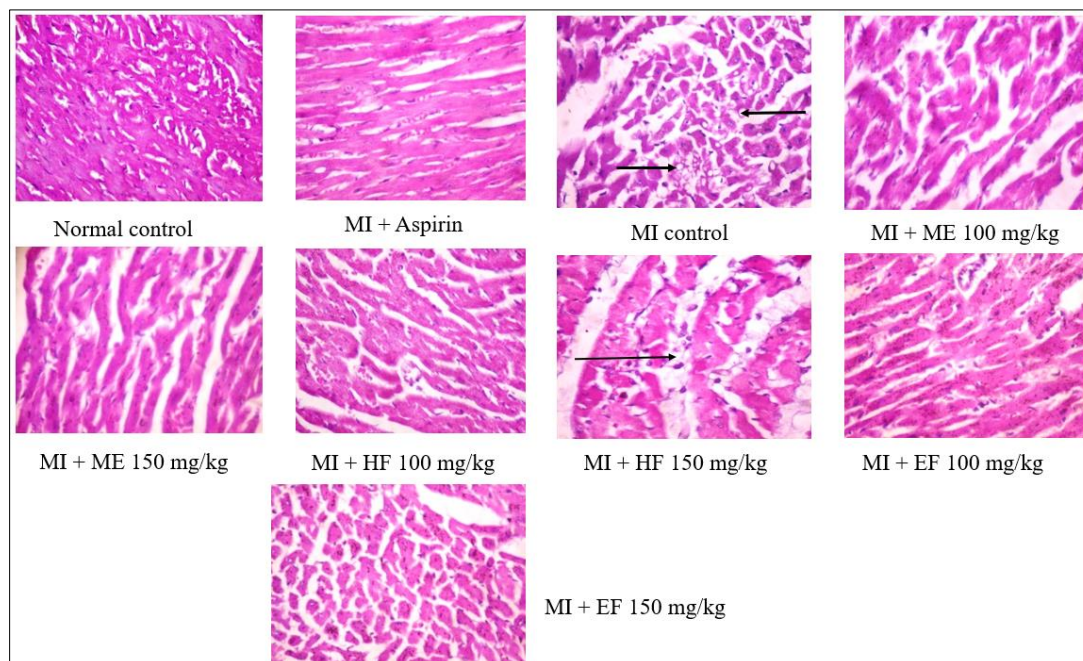


Values were expressed as mean \pm SEM (n=5). Values were statistically significant at $\#p < 0.05$ vs Normal control as analyzed by one-way ANOVA followed by Tukey's multiple comparison test. MI: myocardial infarction, ME: methanol extract, HF: hexane fraction. EF: ethyl acetate fraction

Figure 2 Alanine transaminase activity in the liver of experimental rats

3.4. Effects of *C. rubens* on the pathological changes in the heart of experimental rats

The heart tissue showed the normal histology characterized by normal architecture and cellularity of myocytes in the normal control and some plant-treated groups. In the MI control group, cardiac muscle fiber was disorganized and marked by moderate necrosis and replacement with fibroblasts (fibrosis), enlargement in the size of cardiomyocytes, inflammatory cell infiltration, and fatty degeneration (as indicated by black arrows; Fig. 3). The damages were not observed in some plant pretreated groups and were lower in other groups (Fig. 3).



MI: myocardial infarction, ME: methanol extract, HF: hexane fraction. EF: ethyl acetate fraction. Black arrows indicate inflammatory cell infiltration and fatty degeneration

Figure 3 Effect of *C. rubens* on the histology of the heart of experimental rats, (400 \times , H&E)

4. Discussion

This study was designed to explore the cardioprotective effects of *C. rubens* leaf extracts in an experimental rat model of Isoproterenol-induced myocardial infarction. No significant differences in percentage change in body weight among the *C. rubens* pretreated groups when compared with the normal control group and possibly indicate a comparable growth among the experimental groups. The significantly higher percentage change recorded in the MI of the control and EF treated groups, respectively, may be because of MI toxicity that leads to the reduction of final body weight of the animals.

The effect on organ weight and the ratio of the organ weight to body weight is an important indicator for the identification of the potentially harmful effects of a substance [24]. The present study did not record a significant difference ($p > 0.05$) in the organ-body ratio of the heart and liver of experimental treated groups compared with the normal control. This indicates that the administration of *C. rubens* did not exert or prevent toxicology effects on the tested organs of the experimental rats.

Isoproterenol exerts its toxicological effect by causing certain degrees of damage to the heart clinical indicators, which are related to cardiac myocytes damages [25]. Scientific investigations have shown that during myocardial infarction, several cardiac biomarkers were increased. The explanation for this is that these enzymes were increased in the heart and were released into the bloodstream as a result of membrane breakdown and cardiac muscle cell rupture. As a result, a rise in cardiac enzymes indicates cellular leakage and a loss of functional integrity of the heart's cell membrane [26]. The myocardium contains high concentrations of AST, which are released into the blood when heart tissue is damaged. Thus, AST may be used to evaluate Myocardial infarction [27]. The observed increase in the AST levels in the ISO-induced rats when compared with the normal control indicates a possible compromise in the integrity of the plasma membrane of the tested liver and the heart of the rats. However, the levels of the enzyme in the liver were shown to be comparable to normal control in the groups pretreated with crude extract and solvent fractions of *C. rubens*. This suggests that pretreatment of the rats with crude extract and solvent fractions of *C. rubens* leaves may have prevented the harmful effect of isoproterenol on the liver, as well as the heart. Thus, indicating the ability of the plant to stabilize the organs' plasma membrane as well as repair isoproterenol-induced cardiac tissue damage.

AST and ALT are known to be secreted in reaction to liver injury, in addition to cardiac impairment. AST is more sensitive to heart injury, while ALT is more sensitive to liver disease. As a result, calculating the AST/ALT ratio is critical in determining which organ is the more relevant source [28-29]. The significantly higher levels of AST in the MI control rats in comparison to the normal control group in the current investigation established the deleterious effect of isoproterenol on the cardiac tissues. This was prevented in the experimental rats by the administration of *C. rubens* extract and fractions.

The increased levels of total cholesterol and triglycerides in the ISO-induced group suggest that isoproterenol may interfere with lipid production or metabolism by inhibiting lipoprotein lipase (LPL) production, increasing total cholesterol, and triglyceride levels [29]. Lipoprotein lipase is a triglyceride-degrading enzyme that converts triglycerides to fatty acids. Treatment with *C. rubens* extract and solvent fractions resulted in a dose-dependent reduction in plasma lipid profile levels. The hexane fraction exhibited just a little reduction in total cholesterol. This could indicate that the plant's active ingredients are polar molecules that the hexane solvent could not extract. This suggests that pretreatment of the rats with ME and EF may help to reduce or prevent isoproterenol-induced hyperlipidemia.

Furthermore, the histopathology evaluation revealed pathological changes in the heart in the ISO-induced rats. The cardiac muscle of the MI control rat was marked with cellular injury, patchy necrosis, and enlargement in the size of cardiomyocytes, accompanied by several inflammatory cell infiltration and mild fatty degeneration. These lesions were reduced by various degrees in MI rats pretreated with plant extract and fraction. The outcome of this experiment thus indicates that *C. rubens* extracts can effectively reduce the cardiotoxicity and possible hyperlipidemia caused by isoproterenol.

5. Conclusion

According to the findings of this investigation, *C. rubens* crude extract and solvent fractions exhibited significant hypolipidemic and cardioprotective efficacy in a dose-dependent manner. The crude extract, followed by ethyl acetate, exhibits the most substantial protective effect against the adverse effects of isoproterenol in lipid profiles, and cardiac biomarkers. *C. rubens* could therefore be a novel source of lipid-lowering and cardioprotective agents in pharmaceutical

drug development. Isolation of the plant's components is recommended to determine the exact phytoconstituents responsible for *C. rubens* crude extract and fractions' observed effects.

Compliance with ethical standards

Acknowledgments

The authors greatly appreciate Mr. Taiwo in the Animal Facility of the Department of Biological Sciences, Mountain Top University, Nigeria for technical assistance in animal handling.

Disclosure of conflict of interest

The authors declare no conflict of interest.

Statement of ethical approval

Ethics approval for the experiment was obtained from the health research ethics committee, College of Medicine, University of Lagos, Nigeria (Approval number: CMUL/ACUREC/09/21/926).

References

- [1] Lozano R, Naghavi M, Foreman K, et al. Global and regional mortality from 235 causes of death for 20 age groups in 1990 and 2010: a systematic analysis for the Global Burden of Disease Study 2010 [published correction appears in *Lancet*. 2013 Feb 23;381(9867):628. AlMazroa, Mohammad A [added]; Memish, Ziad A [added]]. *Lancet*. 2012;380(9859):2095-2128. doi:10.1016/S0140-6736(12)61728-0.
- [2] Rastogi, S, Pandey MM, Rawat AK. Traditional herbs: a remedy for cardiovascular disorders. *Phytomedicine: International Journal of phytotherapy and phytopharmacology*. 2016; 23(11): 1082–1089.
- [3] Benjamin E J, Virani SS, Callaway CW, Chamberlain A M, Chang A R, Cheng S, Chiuve SE, Cushman M, Delling FN, Deo R, de Ferranti SD, Ferguson JF, Fornage M, Gillespie C, Isasi CR, Jiménez MC, Jordan LC, Judd SE, Lackland D, Lichtman JH. American Heart Association Council on Epidemiology and Prevention Statistics Committee and Stroke Statistics Subcommittee. Heart Disease and Stroke Statistics-2018 Update: A Report from the American Heart Association. *Circulation*. 2018; 137(12): e67–e492.
- [4] De Alencar Neto JN. Morphine, Oxygen, Nitrates, and Mortality Reducing Pharmacological Treatment for Acute Coronary Syndrome: An Evidence-based Review. *Cureus*. 2018; 10(1): e2114.
- [5] Patrono C, Morais, J, Baigent C, Collet JP, Fitzgerald D, Halvorsen S, Rocca B, Siegbahn A, Storey RF, Vilahur G. Antiplatelet Agents for the Treatment and Prevention of Coronary Atherothrombosis. *Journal of the American College of Cardiology*. 2017; 70(14): 1760-1776.
- [6] El-Anany AM, Ali RFM. Hypolipidemic effect of coffee silverskin in rats fed a high-fat diet. *Food Science and Human Wellness*. 2018; 7: 252–259.
- [7] Khan HA, Alhomida AS, Sobki SA. Lipid Profile of Patients with Acute Myocardial Infarction and its Correlation with Systemic Inflammation. *Biomarker Insights*. 2013; 8: 1–7.
- [8] Villanueva MJ, Yokoyama WH, Hong YJ, Bartley GE, Rupérez P. Effect of high fat diets supplemented with okara soybean byproduct on lipid profiles of plasma, liver and faeces in Syrian hamsters, *Food Chemistry*. 2011; 124: 7279.
- [9] Gupta M. Assessment of lipid profile of patients with acute myocardial infarction: A comparative study. *JMSCR*. 2018; 6(3): 483-486.
- [10] Nayak SB, Pinto Pereira LM, Boodoo S, Kimberlyali A, Baptiste C, Maraj S, Persad N, Khan N, Surendran S, Legall G. Association of troponin T and altered lipid profile in patients admitted with acute myocardial infarction. *Arch Physiol Biochem*. 2010; 116(1): 21-7.
- [11] Zhong Z, Liu J, Li B, Li C, Liu Z, Yang M, Zhang Q, Zhong W, Zhao P. Serum lipid profiles in patients with acute myocardial infarction in Hakka population in southern China. *Lipids in Health and Disease*. 2017; 16(1): 246.
- [12] Stacy AT, Egger A. Results of retrospective chart review to determine improvement in lipid goal attainment in patients treated by high-volume prescribers of lipid-modifying drugs, *J. Manag. Care Pharm*. 2006; 12: 745751.

- [13] Ekor M. The growing use of herbal medicines: issues relating to adverse reactions and challenges in monitoring safety. *Frontiers in pharmacology*, 2014; 4: 177.
- [14] Yuan H, Ma Q, Ye L, Piao G. The Traditional Medicine and Modern Medicine from Natural Products. *Molecules* (Basel, Switzerland). 2016; 21(5): 559.
- [15] Adjatin A, Dansi A, Eze CS, Assogba P, Dossou-Aminon I, Akpagana K, Akoe`gninou A, Sanni A. Ethnobotanical investigation and diversity of Gbolo (*Crassocephalum rubens* (Juss. ex Jacq.) S. Moore and *Crassocephalum crepidioides* (Benth.) S. Moore), a traditional leafy vegetable under domestication in Benin. *Genetic Resources and Crop Evolution*. 2012; 59(8): 1867-1881.
- [16] Ayodele OO, Onajobi FD, Osoniyi O. Modulation of blood Coagulation and hematological Parameters by *Crassocephalum crepidioides* leaf methanol extract and fractions in STZ-induced diabetes in the rat. *The Scientific World Journal*, Volume 2020, Article ID 1036364:1-11. <https://doi.org/10.1155/2020/1036364>
- [17] Das A. Evaluation of the local anaesthetic effect of *Crassocephalum crepidioides* in suitable Experimental Animal Models. *International Journal of Advanced Research (IJAR)*. 2017; 6(2):1831- 1834.
- [18] Grubben JH, Denton OA. *Crassocephalum crepidioides* (Benth.) S.Moore PROTA (Plant Resources of Tropical Africa). *National Horticultural Research journal*. 2018; 50(11): 211-215.
- [19] Aniya Y, Koyama T, Miyagi C, Miyahira M, Inomata C, Kinoshita S, Ichiba T. Free radical scavenging and hepatoprotective actions of the medicinal herb, *Crassocephalum crepidioides* from the Okinawa Islands. *Biological & Pharmaceutical Bulletin*. 2005; 28(1): 19-23.
- [20] Bahar E, Siddika MS, Bashutosh N, Yoon H. Evaluation of In vitro Antioxidant and In vivo Antihyperlipidemic Activities of Methanol Extract of Aerial Part of *Crassocephalum crepidioides* (Asteraceae) Benth S Moore. *Tropical Journal of Pharmaceutical Research*. 2016; 15(3): 481-488.
- [21] Syarifah ASAb, Norzana Abd Ghafar, Zakiah Jubri, Srijit Das. Induction of Myocardial Infarction in Experimental Animals: A Review, *Journal of Clinical and Diagnostic Research*. 2018; 12(11): AE01-AE05 1.
- [22] Nwagha UI, Ikekpeazu EJ, Ejezie FE, Neboh EE, Maduka IC. Atherogenic index of plasma as useful predictor of cardiovascular risk among postmenopausal women in Enugu, Nigeria. *African health sciences*. 2010; 10(3): 248–252.
- [23] Humason GL. Solution preparation and laboratory aids. *Animal tissue techniques*. 4th Edition, W. H. Freeman and Co., San Francisco.1972: 534.
- [24] Ehiwuogu-Onyibe J, Ayodele O, Mordi J, Elemo G. Toxicological safety and weight reduction effect of *Bifidobacterium adolenscentis* CH2 in female albino rats. *African Journal of Microbiology Research*. 2019; 13(10): 195-205.
- [25] Huang H, Geng Q, Yao H, Shen Zh, Wu Zh, Miao X, Shi P. Protective effect of scutellarin on myocardial infarction induced by isoprenaline in rats. *Iranian Journal of Basic and Medical Science*. 2018; 21: 267-276.
- [26] Sabeena FKH, Anandan R, Kumar SH, Shiny KS, Sankar TV, et al. Effect of squalene on tissue defense system in isoproterenol-induced myocardial infarction in rats. *Pharmacology Research*. 2004; 50: 231–236.
- [27] Adeyemi O, Osilesi O, O. Adebawo O, Onajobi F, Oyedemi S, Afolayan A. Alkaline Phosphatase (ALP), Aspartate Aminotransferase (AST) and Alanine Aminotransferase (ALT) Activities in Selected Tissues of Rats Fed on Processed Atlantic Horse Mackerel (*Trachurus trachurus*). *Advances in Bioscience and Biotechnology*. 2015; 6: 139-152.
- [28] Ioannou GN, Weiss NS, Boyko EJ, Mozaffarian D, Lee SP. Elevated Serum Alanine Aminotransferase Activity and Calculated Risk of Coronary Heart Disease in the United States. *Hepatology*. 2006; 43: 1145-1151.
- [29] Pirahanchi Y, Anoruo M, Sharma S. *Biochemistry, Lipoprotein Lipase*. In: *StatPearls*. Treasure Island (FL): StatPearls Publishing; May 8, 2022.