

(CASE REPORT)



## Primary papillary carcinoma in a thyroglossal duct cyst: A case report

Manouchehr Aghajanzadeh <sup>1</sup>, Rastin Hosseinzadeh Asli <sup>1,\*</sup>, Mahtab Raji Lahiji <sup>1</sup>, Pedram Talebi <sup>2</sup>, Abdol Rahim Astanaee <sup>3</sup> and Omid Mosafae <sup>1</sup>

<sup>1</sup> Department of Thoracic and general Surgery, Guilan University of Medical Sciences, Rasht, Iran.

<sup>2</sup> Department of Pathology, Arya hospital, Rasht, Iran.

<sup>3</sup> Department of endocrinology, Iran University of Medical Science, Tehran, Iran.

GSC Advanced Research and Reviews, 2023, 16(02), 069–076

Publication history: Received on 27 June 2023; revised on 04 August 2023; accepted on 07 August 2023

Article DOI: <https://doi.org/10.30574/gscarr.2023.16.2.0332>

### Abstract

**Background:** Thyroglossal duct cyst (TDC) is the most common congenital disorder of the thyroid gland. Seventy five percent of midline neck masses in children are (TDC). Occurrence of malignancy in (TDC) is very rare event, and include 1% of all cases of (TDC). Here in this report, we describe a rare case of primary papillary carcinoma which arises in a (TDC).

**Case report:** Our case is a 42-year-old woman who presented with a hard painless solid and cystic mass in front of the neck above of thyroid cartilage. After initial physical examination and ultrasonography, the mass identified. Radiologist performed a core needle biopsy of the cyst and mass which show a papillary cell carcinoma. The patient underwent near total thyroidectomy, excision of lymph node and surgical excision of the thyroglossal duct cyst (the Sistrunk's procedure). Histopathology of the specimen revealed a thyroglossal duct cyst which showed a primary invasive papillary carcinoma that infiltrated the cyst wall. The thyroid gland was normal, cervical lymph node was not involved.

**Conclusions:** Primary papillary carcinoma of thyroglossal duct cyst is a rare disease which presents in patients with cystic midline neck masses. Surgery and radical excision is the optimal patient management with radioactive iodine therapy which improve the survival.

**Keywords:** Papillary carcinoma; Thyroglossal duct cyst; Sistrunk's procedure; Thyroidectomy; Radioactive iodine therapy

### 1. Introduction

The thyroid gland develops from the endodermal tissues of the primitive gastrointestinal tract. The site of origin ultimately is the foramen caecum at the base of tongue and thyroid descent by the seventh gestational week to lie anterior to the cricoid and on the second and third ring of cervical trachea (1,2,3). The descending of the thyroid through the anterior midline of neck explains several anomalies that relate to thyroid pathology. Along the pathway of thyroid descending, of ciliated pseudo stratified epithelium and variable amounts of thyroid tissue may remain in this pathway which is called thyroglossal duct cysts [1,2].

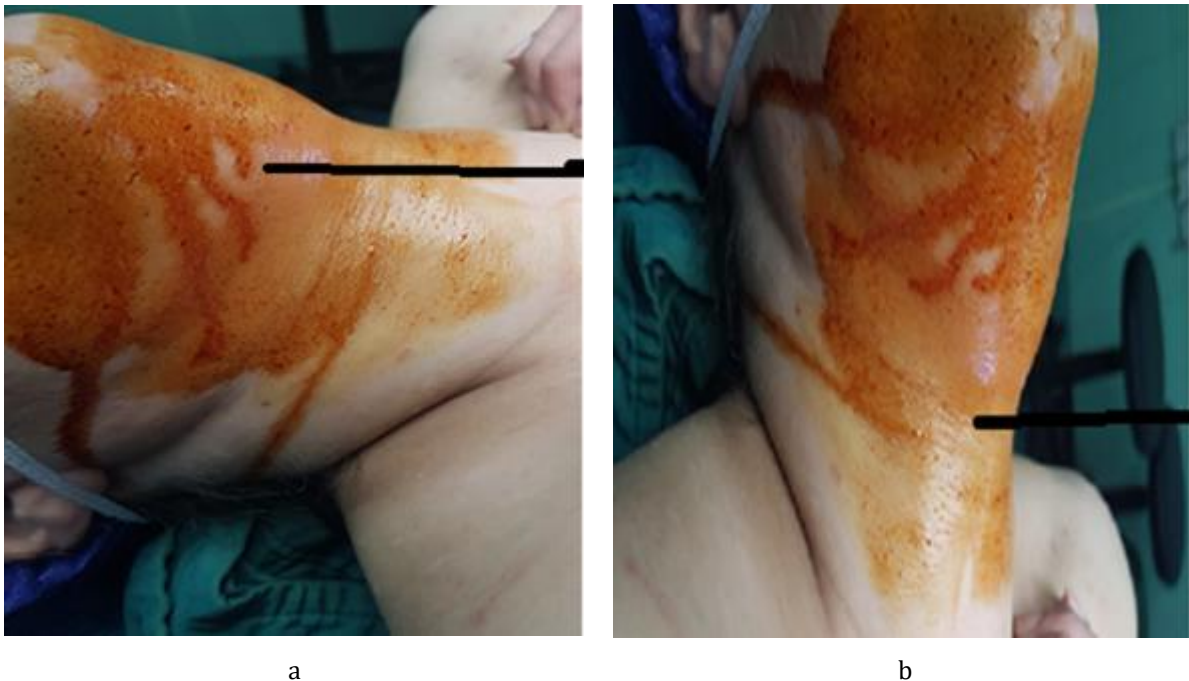
The thyroid gland descends from the foramen caecum to the point below the thyroid cartilage by the seventh week of the intrauterine life (3,4). Thyroglossal duct is the epithelial tract connect the thyroid gland to the foramen caecum (1,3). This duct is normally obliterated in the 8th to 10th week of gestation (1,3). If a complete obliteration is failed, the remaining epithelium in the duct can develop a cystic expansion and form a thyroglossal duct cyst (TDC) (4,5). The most common congenital anomaly in thyroid developmental process is TDC and occurs in 7% of the adult population [2,3].

\* Corresponding author: Rastin Hosseinzadeh Asli; ORCID: 0000-0002-2614-2205

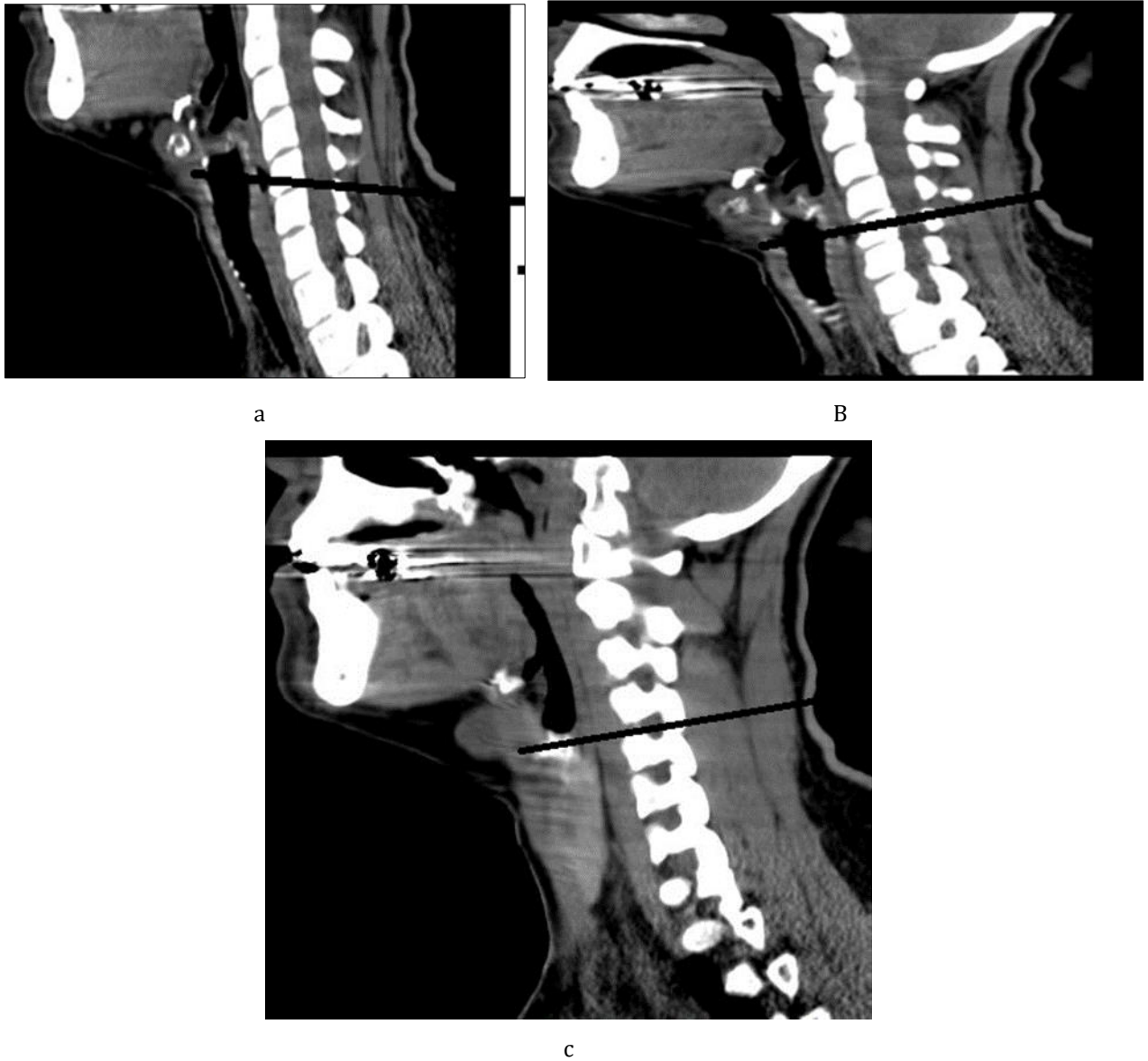
Thyroglossal duct carcinoma is very rare clinical pathology event and occurring in nearly 1% of all the TDC [3,4]. The most common (80%) malignant tumor in TDC is papillary thyroid carcinoma (PTC), followed by mixed papillary-follicular carcinoma (8%), squamous cell carcinoma (6%), follicular carcinoma (3%), adenocarcinoma, and unidentified tumors (3%) [1-4]. The medullary carcinoma has not been reported in the thyroglossal duct cyst [4]. The prognosis of PTC is excellent in the thyroglossal cyst, compared to other rarer types. It should be closely examined by using ultrasonography of neck, computed tomography (CT) scan, and fine-needle aspiration (FNA) test [7]. There is a controversy about thyroglossal duct carcinoma management [3,4,5]. There are different controversies about the value of the Sistrunk procedure [5,6]. The technique of this procedure is a complete resection of cyst with central part of hyoid bone [5,6,7,8], with or without total thyroidectomy [5,6]. In this case report, we present a 42-year-old woman with thyroglossal duct cyst and PTC and discuss the management of the patient with near-total thyroidectomy and radioactive iodine therapy.

## 2. Case Presentation

A 42-year-old woman presented to the endocrinology and oncology clinic with a complaint of an enlarged mass in the midline and above the thyroid cartilage on the anterior aspect of the neck and an enlarged neck mass appeared since the last four months before admission. She was in good health conditions. On physical examination, there was a firm mass on the anterior midline and above part of the neck which is not mobile and has an irregular border. With swallowing, the mass moved to the upper and lower part of the neck and the size of the mass was 6 × 5 × 5 cm (Figure 1a,b). A cervical ultrasound was performed and showed an irregular heterogeneous mass lesion which appeared to be a TDC and a small multinodular goiter. A cervical computed tomography (CT) showed a heterogeneous calcified mass in the anterior region of the neck and compressed the trachea (Fig 2 a,b,c). Before surgery planning, the lesions were diagnosed as a thyroglossal duct cyst (TDC) and a mild nontoxic multinodular goiter. A core needle biopsy was performed by a radiologist. Pathological examination of the mass obtained from the needle biopsy (TDC) revealed papillary thyroid carcinoma. The lower border of the mass was adhesive to the upper portion of both lobes of the thyroid.



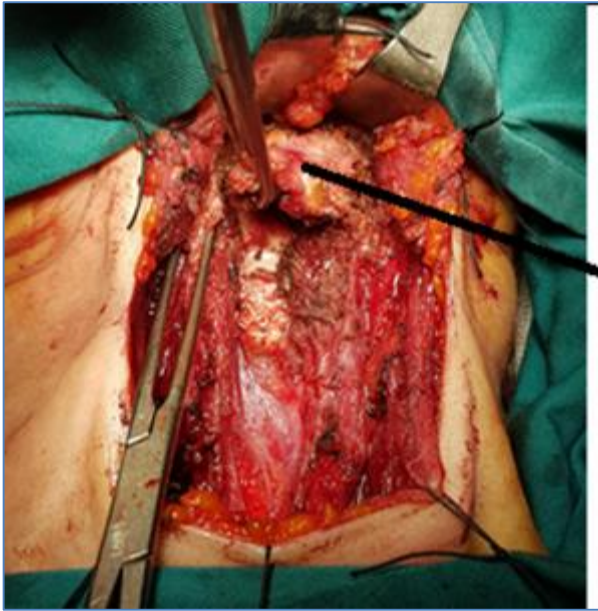
**Figure 1 ( a + b )** Mass of the neck



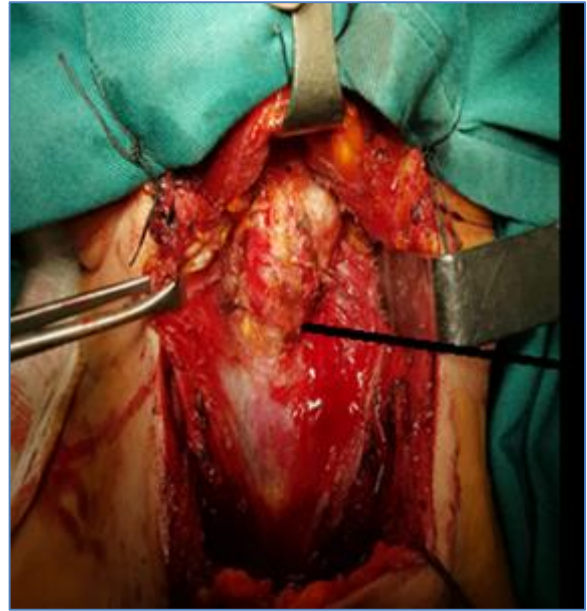
**Figure 2( a + b + c )** CT-scan of neck with TDC mass

Total thyroidectomy and Sistrunk procedure were performed to remove the tumor mass in TDC. The tumor mass of (TDC) has already infiltrated the surrounding tissue, we performed radical surgery of (TDC) with safe margin (Figure 3 abcd) Final pathological examination of the mass obtained from the operation revealed papillary thyroid carcinoma of TDC (10,11). Pathology report of thyroid was normal The patient referred for radioactive iodine ablation.

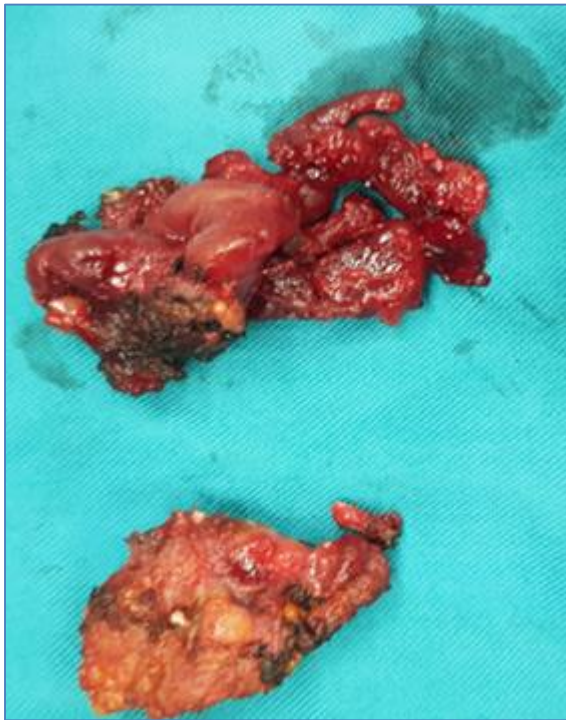




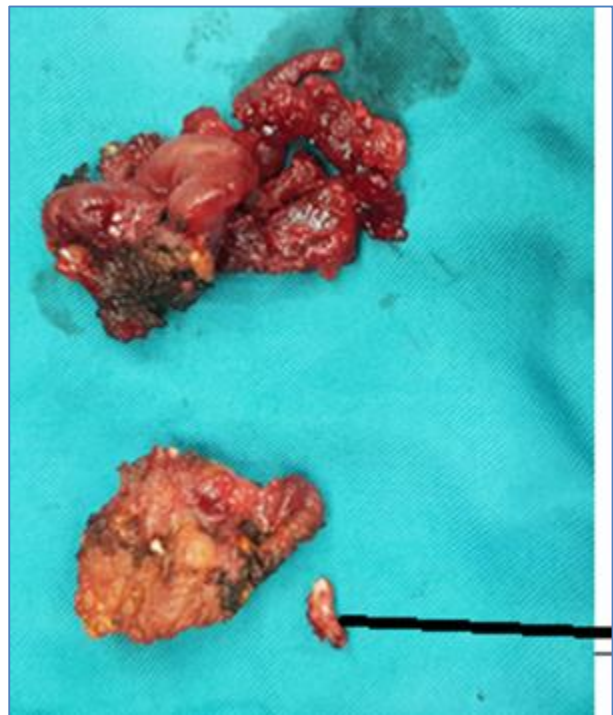
a



b



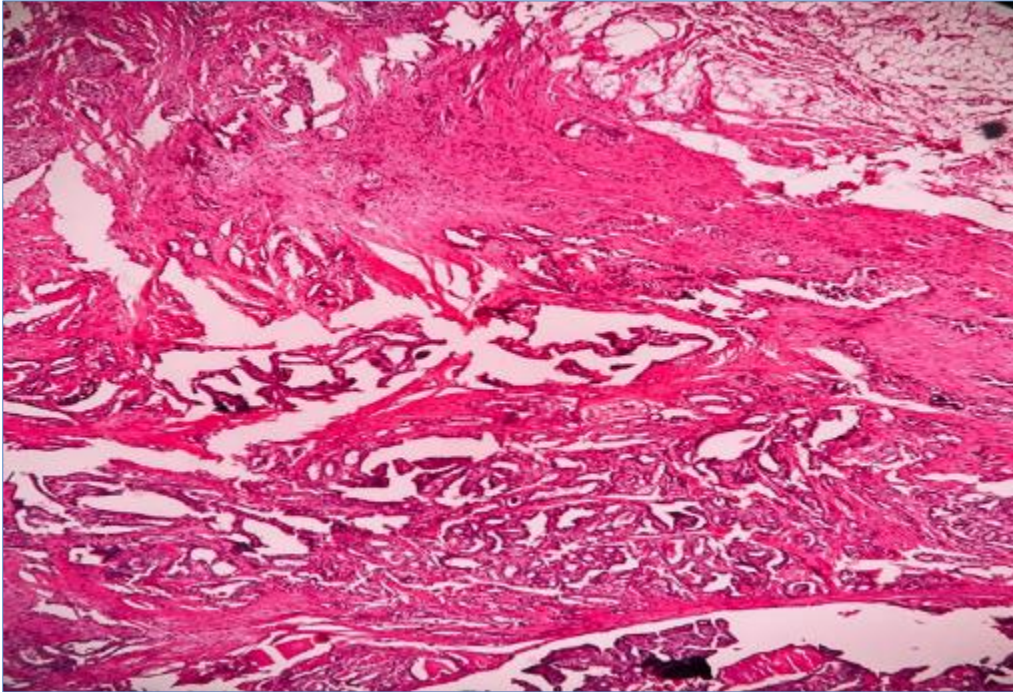
c



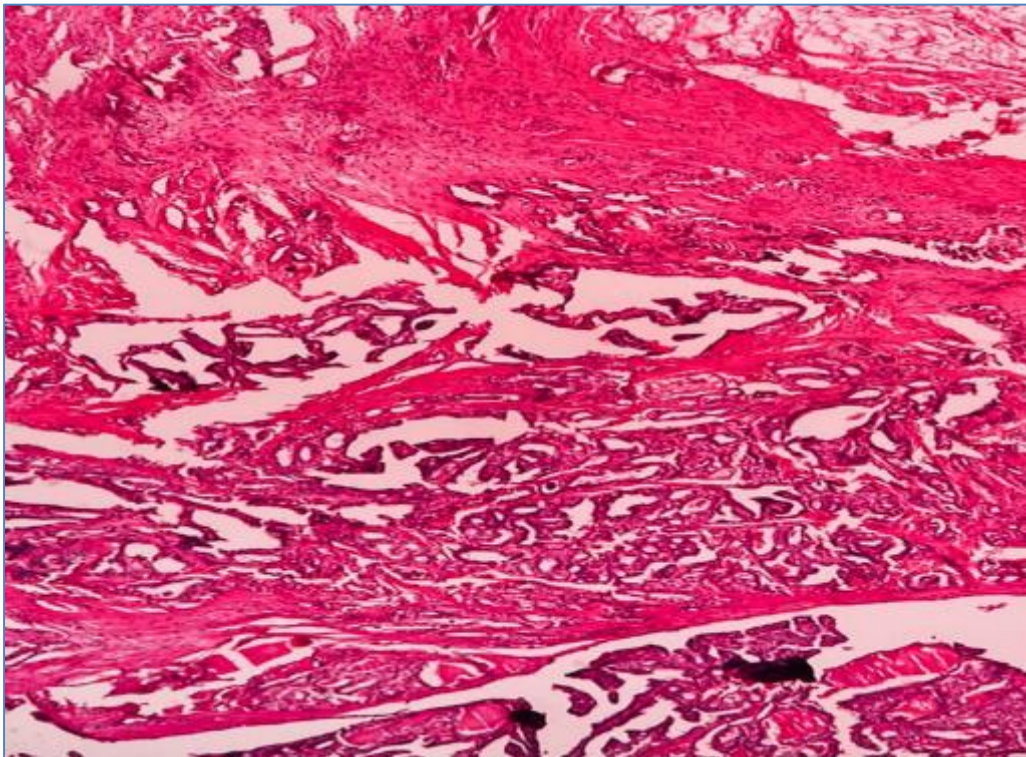
d

**Figure 3( a + b + c + d )** Specimen of mass, hyoid bone and adhesive feature of mass to the thyroid





a



b

**Figure 4( a + b )** Pathology of the mass

### 3. Discussion

When a patient complaint of a neck mass, it is a common clinical finding and has very differential diagnosis, and a systematic approach is required for diagnosis. Most of these masses are benign, but may be primary or metastatic malignant disease (2,5). Thyroglossal duct is the epithelial connection between the thyroid gland and the foramen cecum during migration of thyroid process (4,5). Normally, the Thyroglossal duct will be completely closed at the 8th to 10th week of pregnancy (2,6). If this connection failure to close the remaining epithelium tissue lead to the development of a thyroglossal duct, most typically present as a cysts [1,6]. TDC are common congenital neck mass which present in the neck and were found in 7% of adult population but it is rare in children [2,8]. Although TDCs are usually benign, may develop carcinoma in it about 1% of cases and the cause is ectopic thyroid tissue in the cyst (9,10). This entity was first reported by Brentano (1911) [4,6,7,], few cases have been reported until today [5]. The cause of TDC carcinoma is unclear, the most common theories are either it is metastasis from an occult primary thyroid papillary carcinoma or from ectopic thyroid tissue in the TDC (4,10,11,14). Some believe that there are two theories which can explain this event, one is spread from a primary thyroid gland tumor [4]. Most authors believe the ectopic thyroid tissue in the cyst wall rather more than the metastatic spread from a primary thyroid gland tumor (9,10,12). One of other theory is synchronous occurrence of thyroglossal duct cyst carcinoma and thyroid carcinoma, usually this kind of tumors are multifocal [6]. Carcinoma found in < 1% of TGD cyst (8) F:M = 2:1, mean age 40 years (range 6 to 84 years), our case age was 42 years and was female. Mean age of children are 12 years (9) The most common cancer in TDC is classic papillary thyroid carcinoma (90%), however follicular and tall cell variants are also reported (< 10%), squamous cell carcinoma in (5%), follicular carcinoma in (2% - 3%) (10). Anaplastic carcinoma, mucoepidermoid, adenosquamous may involve rarely in TDC (11). In our case final diagnosis was PTC. Most TGD carcinomas are asymptomatic and are discovered incidentally by the pathologist after surgery of TDC, but in our case diagnosis was performed with needle biopsy by radiologist before surgery.

Preoperative diagnosis is difficult and there no symptoms and sign between a benign and malignancy cyst (TDC) (11). Malignancy can be suspected if Sudden enlargement of preexisting cyst, Hard, fixed and irregular mass, cervical lymph adenopathy, history of neck irradiation (10). Our patient present with hard mass above anterior portion of neck above thyroid cartilage. Occult carcinoma in normal thyroid gland found in 30% - 60% of TGD cyst cases after thyroidectomy (11). Preoperative diagnosis of carcinoma in a patient with TGD cyst is difficult. Neck ultrasound, CT -scan, MRI and FNAC or core needle biopsy can helpful to diagnosis (11,12). histopathological confirm the definitive diagnosis of thyroglossal remnants in a specimen with carcinoma (11,14). FNA cytology has low sensitivity, but core needle biopsy has high sensitivity and intraoperative frozen sections are diagnostic modality (12,15). our primary diagnosis tool was core-needle biopsy. Mesolella criteria for diagnosis of TDC carcinoma :include a thyroglossal remnant, ectopic thyroid nests within the cyst wall, and a clinically normal thyroid gland (13). Park criteria for diagnosis is with histopathological examination (14). A primary carcinoma of the thyroglossal duct usually rise from epithelial lining of cyst by normal thyroid follicles and within the cysts wall and normal thyroid tissue around the tumor and thyroid gland showing no sign and symptoms of primary carcinoma and are occult [14]. The main problems and controversies are the diagnosis and the management of this malignancy which present in a TDC (9,10,11). Malignant or benign TDC masses are commonly mistaken from others mass which presence at the anterior neck region (5,7). Preoperative evaluation of thyroglossal duct cyst includes examination head and neck, palpation of thyroid gland, and imaging tools (1,2,7). Diagnosis of malignancy cannot usually be perform preoperatively by imaging tools (ultrasound, scintigraphy, and CT-scan) [14]. Fine needle aspiration biopsy can only give a correct diagnosis in about 53–66% of the cases [14,15,]. The diagnosis of malignancy arising in TDC is confirm by histopathological examination of the cyst (9,11,14). In literature reviewed most of the carcinoma was not suspected before surgery but after surgery histopathological examination of samples confirm the diagnosis [16]. In our patient definitive diagnosis was performed before resection by core-needle biopsy. Because TDC carcinoma is a rare case and preoperative diagnosis is difficult and there is not in the literature the optimal management for TDC carcinoma [16,17,18]. But we recommended core-needle biopsy of TDC can help the diagnosis and in the most case reports, they recommended radical resection of TDC tumor and total thyroidectomy (9,10,13,14,18)

Sistrunk's procedure is the surgical procedure which performed commonly for a thyroglossal duct cyst (17,18). This procedure consists of removal of the thyroglossal duct cyst, the medial segment of the hyoid bone, and a core of tissue around the duct (19,20,21). If histological examination does not show extra cystic extension, in such condition some surgeons believe the Sistrunk's procedure is adequate [17], Other literatures recommended more aggressive surgical approaches if papillary thyroid carcinoma may extension through the thyroglossal duct remnant (13,17) Those literatures recommended the treatment of these patients include: Sistrunk procedure, total thyroidectomy, postoperative radioactive iodine therapy, and thyroid hormone replacement post surgery [13,17]. In our case we resect radically the mass of TDC carcinoma with around tissue with near total thyroidectomy and central portion of hyoid bone

K. Luna-Ortiz believe, after Sistrunk procedure for remove of TDC mass, if histological examination reveals malignancy, the thyroid gland must be studied with radiological and scintigraphic [18]. Some studies show the incidences of primary thyroid carcinoma with TDC carcinoma are about 11–45%, in such case total thyroidectomy should be perform [3, 4]. If there is cystic wall invasion by the carcinoma or if the TDC carcinoma is greater than 1.5 cm a total or subtotal thyroidectomy has been recommended [19]. Thyroid suppression therapy with thyroxin is recommended for all this patients [1,2,3,20].

Some study reported that behaviors of papillary carcinoma in TDC is as general papillary carcinoma of thyroid and may present lymph node metastasis [13,14]. When lymph node metastases are found on ultrasound or during surgery, neck dissection is should performed (21,22). The type of neck dissection is limited to central portion of neck[21,22]. In our patients, we did not find lymph node in the neck. Therefore, as a guideline recommended by most of the oncology centers, lateral neck dissection was not need(21,22).

The prognosis for papillary carcinoma of TDC is excellent, debside with occurrence of metastatic{is less than 2% of cases }[3]. In some reports histopathology showed papillary thyroid carcinoma as tall cell variant in the TDC and in the thyroidectomy area[18,23,24]. The mortality in the tall cell variant group was higher more than classic papillary thyroid carcinoma (18, 23). A study shown that tall cell variant patients have higher rate of recurrence and mortality [24]. 5-year survival was poorer in the tall cell variant group is low (24).But in the classic papillary thyroid carcinoma the survival is excellent. Histopathologic examination in our case after resection was classic papillary thyroid carcinoma.

#### *Abbreviation*

- PTC= Papillary Thyroid Carcinoma
- TDC= Thyroglossal Duct Cyst
- TGD= Thyroglossal Duct
- FNA= Fine Needle Aspiration

---

#### **4. Conclusion**

Literature review show that occurrences of thyroid carcinoma is very rare in a TDC. Surgeons and clinicians must be aware during examination and evaluation of all neck mass especially when located around hyoid bone or above thyroid cartilage, TDC must be in differential diagnosis[2]. with physical examination, malignancy may be suspected in a TDC. Preoperative coor- needle biopsy can help for diagnosis. With the process of embryological development of the thyroid, the ideal treatment for this malignancy of the thyroglossal duct is Sistrunk's procedure and total thyroidectomy.

---

#### **Compliance with ethical standards**

##### *Disclosure of conflict of interest*

No conflict of interest to be disclosed.

##### *Statement of informed consent*

Informed consent was obtained from all individual participants included in the study.

---

#### **References**

- [1] L. B. Harrison, R. B. Sessions, and W. K. Hong, Eds., Head and Neck Cancer: A Multidisciplinary Approach, Lippincott, William & Wilkins, Philadelphia, Pa, USA, 3rd edition, 2009.
- [2] Choi YM, Kim TY, Song DE, Hong SJ, Jang EK, Jeon MJ, et al. Papillary thyroid carcinoma arising from a thyroglossal duct cyst: a single institution experience. Endocrine journal. 2012; 60(5):665-703.
- [3] L. Aghaghazvini, H. Mazaher, H. Sharifian, S. Aghaghazvini, and M. Assadi, Invasive thyroglossal duct cyst papillary carcinoma: a case report, Journal of Medical Case Reports, vol. 3, article 9308, 2009.
- [4] N. Balalaa, M. Megahed, M. Al Ashari, and F. Branicki, Thyroglossal duct cyst papillary carcinoma, Case Reports in Oncology, vol. 4, no. 1, pp. 39–43, 2011.
- [5] Doshi SV, Cruz RM, Hilsinger Jr RL. Thyroglossal Duct Carcinoma: A large Case Series. Annals of Otology, Rhinology & Laryngology. 2001;110(8):734-8

- [6] Peretz A, Leiberman E, Kapelushnik J, Hershkovitz E. Thyroglossal duct carcinoma in children: case presentation and review of the literature. *Thyroid*. 2004;14(9):777-85
- [7] Ramalingam R, Ramalingairr K, Ramesh A, Prabhu SM, Vergis M, Ahilasamy N. Papillary thyroid carcinoma in a thyroglossal cyst. *Indian Journal of Otolaryngology and Head & Neck Surgery*. 2003; 55(4):294-5.
- [8] Ho Min Yun, Chen Yong Lee York Tien, Michaela Su-Fern Seng, Lau Hiu Yeung, Constance Ee Hoon Teo, Tay Ze Yun, Amos Hong Pheng Loh, Thyroglossal Duct Cyst Carcinoma in The Pediatric Population: A Case Report and Literature Review, *Med Case Rep* 2022; 3(5): 1-13.
- [9] Asaf Peretz, Esther Leiberman, Joseph Kapelushnik, Eli Hershkovitz: Thyroglossal duct carcinoma in children: case presentation and review of the literature. *Thyroid*. 2004 Sep; 14(9):777-85.
- [10] Marica Zizic, William Faquin, Antonia E Stephen, Dipti Kamani, Romy Nehme Cristian M Slough, Gregory W Randolph, Upper neck papillary thyroid cancer (UPTC): A new proposed term for the composite of thyroglossal duct cyst-associated papillary thyroid cancer, pyramidal lobe papillary thyroid cancer, and Delphian node papillary thyroid cancer metastasis: *Laryngoscope*, 2016 Jul; 126(7):1709-14
- [11] Shuanzeng Wei, Virginia A LiVolsi, Zubair W Baloch, Pathology of thyroglossal duct: an institutional experience, *Endocr Pathol*. 2015 Mar; 26(1):75-9.
- [12] Debora L S Danilovic, Suemi Marui, Erika U Lima, Arthur V C Luiz, Marilia D E G Brescia, Raquel A Moyses, Claudio R Cernea, Lenine G Brandão, Maria C Chammas, André B O Santos. Papillary carcinoma in thyroglossal duct cyst: role of fine needle aspiration and frozen section biopsy to guide surgical approach, *Endocrine*. 2014 May; 46(1):160-3
- [13] Mesolella, F. Ricciardiello, M. Cavaliere, M. Iengo, V. Galli, and J. Galli, Papillary carcinoma arising in a submental-intraliquinal thyroglossal duct cyst, *Acta Otorhinolaryngologica Italica*, vol. 30, no. 6, pp. 313–316, 2010
- [14] M.-H. Park, J.-H. Yoon, Y.-J. Jegal, and J.-S. Lee, Papillary thyroglossal duct cyst carcinoma with synchronous occult papillary thyroid microcarcinoma, *Yonsei Medical Journal*, vol. 51, no. 4, pp. 609–611, 2010
- [15] Y. J. Yang, S. Hagher, J. R. Wanamaker, and C. N. Powers, Diagnosis of papillary carcinoma in a thyroglossal duct cyst by fine-needle aspiration biopsy, *Archives of Pathology and Laboratory Medicine*, vol. 124, no. 1, pp. 139–142, 2000;
- [16] T. Kandogan, N. Erkan, and E. Vardar, Papillary carcinoma arising in a thyroglossal duct cyst with associated microcarcinoma of the thyroid and without cervical lymph node metastasis: a case report, *Journal of Medical Case Reports*, vol. 2, article 42, 2008.
- [17] M. A. Ali, A. Abussa, and H. Hashmi, Papillary thyroid carcinoma formation in a thyroglossal cyst. A case report, *Libyan Journal of Medicine*, vol. 2, no. 3, pp. 148–149, 2007.
- [18] K. Luna-Ortiz, L. M. Hurtado-Lopez, J. L. Valderrama-Landaeta, and A. Ruiz-Vega, Thyroglossal duct cyst with papillary carcinoma: what must be done? *Thyroid*, vol. 14, no. 5, pp. 363–366, 2004
- [19] E. A. Pribitkin and O. Friedman, Papillary carcinoma in a thyroglossal duct remnant, *Archives of Otolaryngology: Head and Neck Surgery*, vol. 128, no. 4, pp. 461–462, 2002
- [20] K. Kant and G. Rajpal, Papillary carcinoma arising in a thyroglossal duct remnant, *Indian Journal of Surgery*, vol. 65, no. 3, pp. 282–284, 2003
- [21] S.-I. Yang, K.-K. Park, and J.-H. Kim, Papillary carcinoma arising from thyroglossal duct cyst with thyroid and lateral neck metastasis, *International Journal of Surgery Case Reports*, vol. 4, no. 8, pp. 704–707, 2013.
- [22] S.-I. Yang, K.-K. Park, and J.-H. Kim, Papillary carcinoma arising from thyroglossal duct cyst with thyroid and lateral neck metastasis, *International Journal of Surgery Case Reports*, vol. 4, no. 8, pp. 704–707, 2013
- [23] L. G. T. Morris, A. R. Shaha, R. M. Tuttle, A. G. Sikora, and I. Ganly, Tall-cell variant of papillary thyroid carcinoma: a matched-pair analysis of survival, *Thyroid*, vol. 20, no. 2, pp. 153–158, 2010
- [24] S. Jalisi, T. Ainsworth, and M. La Valley, Prognostic outcomes of tall cell variant papillary thyroid cancer: a meta-analysis, *Journal of Thyroid Research*, vol. 2010, 4 pages, 2010.