

(REVIEW ARTICLE)



## Lung ultrasound versus chest radiography for diagnosing pneumonia: A mini systematic review

Sulistiyani Kusumaningrum <sup>1</sup>, Adam Prabata <sup>2</sup>, Luths Maharina <sup>3</sup>, Yusuf Syaeful Nawawi <sup>1</sup> and Muchtar Hanafi <sup>1,\*</sup>

<sup>1</sup> Radiology department, Dr. Moewardi Public Hospital, Faculty of Medicine, Sebelas Maret University, Surakarta, Indonesia.

<sup>2</sup> Cardiovascular division, School of Medicine, Kobe University, Japan.

<sup>3</sup> Radiology department, PKU Muhammadiyah Karanganyar Hospital, Indonesia.

GSC Advanced Research and Reviews, 2021, 07(03), 122–125

Publication history: Received on 18 May 2021; revised on 25 June 2021; accepted on 28 June 2021

Article DOI: <https://doi.org/10.30574/gscarr.2021.7.3.0131>

### Abstract

**Background:** Pneumonia is a deadly disease which needs fast and correct examination and therapy. Some studies suggest that lung ultrasound could be useful and fast examination for diagnosing pneumonia. Furthermore, it has more favorable safety profile and lower cost than chest X-ray (CXR) and Computed Tomography (CT).

**Objective:** The aim of this study is to know accuracy of lung ultrasound versus chest radiography for diagnosing pneumonia and whether it can replace chest radiography as routine examination.

**Methods:** We made structured research on several databases including Science direct, Proquest, Pubmed, and EBSCO Host. The selected studies underwent critical appraisal based on Oxford CEEBM diagnostic study clinical appraisal.

**Results:** Six diagnostic studies comprising of 752 participants met inclusion criteria were critically appraised. Sensitivity of lung ultrasound in pneumonia is better than chest radiography (68%-98.5% vs. 47%-77.7%). Specificity of lung ultrasound is better than chest radiography in pneumonia (57%-98.5% vs. 59.5%-94%). All of studies showed lung ultrasound is better and statistically significant.

**Conclusions:** Our study indicates that lung ultrasound is better than chest radiography for diagnosing pneumonia and can become routine examination. It may represent a useful first-line approach for confirmation of clinical diagnosis.

**Keywords:** Lung ultrasonography; Chest radiography; Pneumonia

### 1. Introduction

Pneumonia ranks as the third cause of death worldwide, preceded only by ischemic heart disease and cerebrovascular diseases. It is the leading infectious cause of death and one of the most common reasons for emergency room (ER) visits and hospital admissions. In patients with clinically suspected pneumonia, a correct differential diagnosis is essential for proper treatment orientation. Diagnostic and treatment delays and failure can entail a significant increase in mortality, while inappropriate use of antibiotics to treat respiratory symptoms that are not secondary to bacterial infection contributes to the development of antibiotic resistance [1].

Traditionally, the diagnosis of pneumonia is based on three mainstays: clinical and laboratory data, imaging techniques, and microbiological studies [2]. International guidelines recommend the use of chest x-ray as first line examination, despite its low sensitivity and specificity [3]. Besides, image quality is lower in patients in decubitus position and when using portable devices; it implies patient mobilization, radiation exposure, and high interobserver variability [4].

\* Corresponding author: Muchtar Hanafi

Radiology department, Dr. Moewardi Public Hospital, Faculty of Medicine, Sebelas Maret University, Surakarta.

Thoracic computed tomography (CT) scan, although considered as the gold standard, is often not performed and involves an important exposure to ionizing radiations, limiting its use to difficult cases [2]. Its use is reserved for more complex cases and where therapeutic failure occurs. Its main drawbacks are the need to transfer the patient to the X-ray unit and high cost [5].

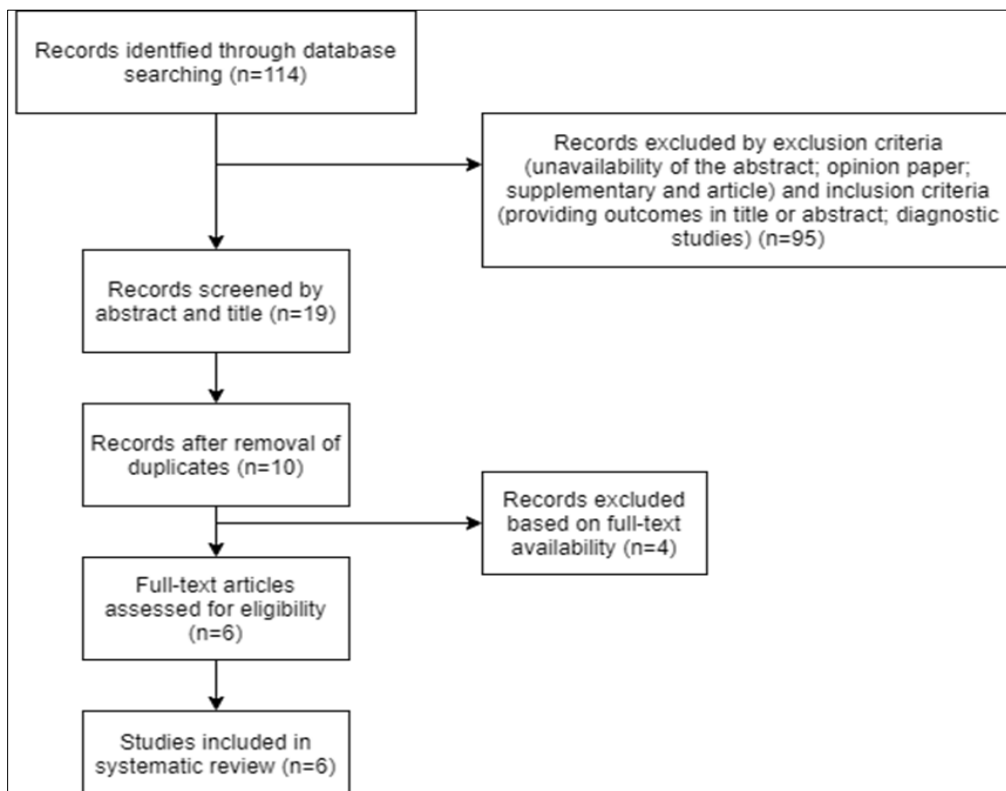
In this context, and although it is not considered in current clinical practice guidelines, bedside lung ultrasound for pneumonia has attracted interest in recent years because it is portable and fast, does not use radiation, is easily reproducible, and allows real-time scanning. Available data also suggest high diagnostic performance [6].

The aim of this mini systematic review is to know accuracy of lung ultrasound versus chest radiography for diagnosing pneumonia and whether it can replace chest radiography as routine examination.

## 2. Methods

We made structured research on several databases including Sciencedirect, Proquest, Pubmed, and EBSCOHost. We included studies in people aged 18 years and older with clinical suspicion or confirmed diagnosis of pneumonia, comparing lung ultrasound versus chest radiography.

Computerised PubMed, ScienceDirect, EBSCOHost, and Proquest searches were performed in 20 February 2021. With few restrictions only for english language, published in the last 10 years, and studied in human. Our search is also restricted to article or journal only. Index and free-text search terms included 'pneumonia' and ('ultrasonography' or 'ultrasound') and 'chest radiograph'. We independently performed the preliminary screening based on titles and abstracts, to include potentially relevant articles. After the first screening, studies were retrieved in full text to check eligibility according to inclusion criteria and exclusion criteria. We exclude article with no abstract, opinion paper, supplementary and review article. We include all diagnostic studies with outcomes in title or abstract. In order to provide greater comprehensiveness to the review, we did not use any age filters despite the fact that potentially eligible studies had to be in adults; we reviewed the full text of any studies involving children to identify possible subgroups of adults. The selected studies then underwent diagnostic study critical appraisal.



**Figure 1** Searching strategies algorithm

### 3. Results

For each included study, two researchers (LM and AP) manually extracted data concerning the number of true positives, false positives, true negatives, and false negatives. In cases where this information was not explicitly reflected, 2x2 tables for calculating the required data were constructed.

The initial literature search yielded a total of 114 studies, 6 of which met the inclusion criteria and were included in the qualitative and quantitative synthesis. The predominant design was the cohort study (Tables 1) and all took place between 2013 and 2015. Most studies were European, and altogether they involve a total of 752 participants.

Sensitivity of lung ultrasound in pneumonia is better than chest radiography (68%-98.5% vs. 47%-77.7%). Specificity of lung ultrasound is better than chest radiography in pneumonia (57% -98.5% vs. 59.5%-94%). All of studies showed lung ultrasound is better and statistically significant.

**Table 1** Characteristics of included studies

	Country	Design	Blind in LUS	Blind in gold standard
Corradi F, et al (2014)	Italy	Cohort	Yes	Yes
Bourcier JE, et al (2013)	France	Cohort	Yes	Yes
Pagano, et al (2015)	Italy	Cohort	Yes	Yes
Nazerian P, et al (2015)	Italy	Cohort	Yes	Yes
Ticinesi A, et al (2015)	Italy	Cohort	Yes	Yes
Liu X, et al (2014)	China	Cohort	Yes	Yes

**Table 2** Critical appraisal and analysis of selected studies

	Sample	Disease	USG		CXR		p-value
			Sensitivity	Specificity	Sensitivity	Specificity	
Corradi F, <i>et al</i> (2014)	32	Pneumonia	68%	95%	64%	80%	p<0.01
Bourcier JE, <i>et al</i> (2013)	144	Pneumonia	95%	57%	68%	76%	p<0.01
Pagano, <i>et al</i> (2015)	105	Pneumonia	98.5%	64.9%	73.5%	59.5%	p<0.001
Nazerian P, <i>et al</i> (2015)	190	Pneumonia	81.4%	94.2%	64.3%	90%	p<0.05
Ticinesi A, <i>et al</i> (2015)	169	Pneumonia	92%	94%	47%	93%	p<0.05
Liu X, <i>et al</i> (2014)	112	Pneumonia	94.6	98.5%	77.7%	94%	p<0.001

### 4. Discussion

The results of our study suggest that bedside lung ultrasound has an excellent accuracy for the diagnosis of pneumonia in adults. Corradi et al. showed lower sensitivity of either lung ultrasound or chest radiograph because they conducted on a small number of sample (n=32) [8]. Overall, our study showed significant differences between lung ultrasound and chest radiograph in detecting pneumonia, although most of the included studies have problem regarding risk of bias.

Our findings are consistent with previous systematic reviews, although we only included 6 studies due to our inclusion and exclusion criteria. Systematic review by Chavez et al [7] and Alvarez et al. showing more favorable data on the diagnostic accuracy profile of the lung ultrasound. Chavez et al. obtained a weighted sensitivity and specificity of 94% and 96%, which included 10 studies. Chavez et al. also included at least one study in which the unit of analysis was not

the participant [7]. Alvarez et al [6] obtained sensitivity 80% to 90% and a specificity of 70% to 90%, they were included 16 studies. The main differences with our review are related to methodology and to the inclusion of fewer studies.

In addition to its diagnostic accuracy, lung ultrasound has other advantages over CXR and CT, as it can be done quickly at bedside, is easily reproducible, has a relatively low cost, and avoids any exposure to ionizing radiation [1]. On the other hand, ultrasounds are of limited value in patients with subcutaneous emphysema and in obese people due to the thickness of the chest wall [4]. Moreover, it is not possible where access to the patient's chest is limited by large bandages, prosthetic material, or skin disorders. Another disadvantage of lung ultrasound is its observer-dependent nature, as it implies the need for operators with certain skills and experience; however, the learning curve is relatively fast and in the end the method can obtain high interobserver agreement [3].

---

## 5. Conclusion

Our study indicates that lung ultrasound is better than chest radiography for diagnosing pneumonia and could become routine examination. It may represent a useful first-line approach for confirmation of clinical diagnosis.

---

## Compliance with ethical standards

### *Acknowledgments*

We would like to thank to the Director of Dr. Moewardi General Hospital and the head of radiology residency program for their support of making this systematic review.

### *Disclosure of conflict of interest*

There is no conflict of interests. The authors report no conflicts of interest in this work. By this statement, all authors who consist of Sulistyani Kusumaningrum, Adam Prabata, Luths Maharina, Yusuf Syaeful Nawawi, Muchtar Hanafi have no conflict of interest regarding this manuscript publication.

### *Statement of informed consent*

Informed consent was obtained from all individual participants included in the study through hospital medical record accessing permission.

---

## References

- [1] Nazerian P, Volpicelli G, Vanni S, *et al.* Accuracy of lung ultrasound for the diagnosis of consolidations when compared to chest computed tomography. *Am J Emerg Med.* 2015; 33(5): 620-625.
- [2] Pagano A, Numis FG, Visone G, Pirozzi C, *et al.* Lung ultrasound for diagnosis of pneumonia in emergency department. *Intern Emerg Med.* 2015; 10: 851-854.
- [3] Bourcier J, Paquet J, Seinger M, *et al.* Performance comparison of lung ultrasound and chest x-ray for the diagnosis of pneumonia in the ED. *Am J Emerg Med.* 2014; 32(2): 115-118.
- [4] Liu X, Lian R, Tao Y, Gu C, Zhang G. Lung ultrasonography: An effective way to diagnose community-acquired pneumonia. *Emerg Med J.* 2015; 32(6): 433-438.
- [5] Brenner DJ, Hall EJ. Computed tomography-an increasing source of radiation exposure. *N Engl J Med.* 2007; 357(22): 2277-2284.
- [6] Alvarez AML, Lozano EMT, Perez JL. Accuracy of lung ultrasound in the diagnosis of pneumonia in adults: systematic review and meta-analysis. *Chest.* 2016.
- [7] Chavez MA, Shams N, Ellington LE, *et al.* Lung ultrasound for the diagnosis of pneumonia in adults: A systematic review and meta-analysis. *Respir Res.* 2014; 15(1).
- [8] Corradi F, Brusasco C, Garlaschi A, Paparo F, Ball L, Santori G, *et al.* Quantitative analysis of lung ultrasonography for the detection of community-acquired pneumonia: a pilot study. *Biomed Research Int.* 2015.
- [9] Ticcinesi A, Lauretani F, Nouvenne A, Mori G, *et al.* Lung ultrasound and chest x-ray for detecting pneumonia in an acute geriatric ward. *Medicine.* 2016.