



(RESEARCH ARTICLE)



Genotoxic and histopathological alterations in rats exposed to herbal liquors

Eniola Olatundun Bolawa ^{1,*}, Busayo Mariam Adeogun ¹ and Rose Anthonia Alani ²

¹ *Biochemistry Department, University of Lagos, College of Medicine, Idi-Araba, Lagos State, Nigeria.*

² *Chemistry Department, University of Lagos, Akoka, Lagos State, Nigeria.*

GSC Biological and Pharmaceutical Sciences, 2021, 17(03), 198–216

Publication history: Received on 04 November 2021; revised on 19 December 2021; accepted on 21 December 2021

Article DOI: <https://doi.org/10.30574/gscbps.2021.17.3.0353>

Abstract

The increase in consumption of herbal liquors in Nigeria is a cause for alarm. These are consumed with the misconception that they are without toxic effects. The aim of this study is to investigate the genotoxic and histopathological alterations in rats exposed to herbal liquors. Female rats were exposed to herbal liquors for 6 weeks. The histopathological and genotoxic evaluation were done to assess extent of damage. Pathological examination revealed incidences of aggregates chronic inflammatory cell infiltrates in the heart of Jedi treated group while the heart of the other groups had no abnormalities. The histologic sections of the kidney tissue revealed congested vessels while the lung showed reduction in air filled alveolar spaces with infiltration of alveoli and interstitium by aggregates of inflammatory cells indicating moderate to severe pulmonary inflammation. Histologic sections of lung tissue in rats treated with herbal liquors reveals congestion of pulmonary vessels and interstitial hemorrhages. Genotoxic evaluation of rat lymphocytes exposed to herbal liquors via comet assay shows that rats administered with the different herbal liquors developed significant ($p < 0.05$) as revealed in the % DNA in tail, % DNA in head, olive moment, tail length and tail moment which indicates the presence of DNA strand breaks and a marker for oxidative DNA damage. This result reveals that herbal liquors contain substances that produce reactive oxygen species that have pathological effect on certain organs as well as inducing DNA strand breaks that could compromise the integrity of the DNA which can lead to mutation.

Keywords: Genotoxicity; Histopathology; Herbal Liquors; Heart tissue; Kidney tissue; Herbal Medicinal Drinks

1. Introduction

The increase in the intake of herbal liquors in Nigeria is alarming as these herbal liquors are consumed with the idea that herbs are natural and has no toxic effects. However, herbal liquors may contain toxic materials that are detrimental or have harmful effects after a long period of consumption.

In spite of the large commercial sale of herbal remedies, little data exist to support their medicinal claims. Also, there are no scientific data on the safety of these herbal liquors (1;2).

The World Health Organization (WHO) reported that about 80% of the people in developing countries depend on herbal medicinal products. The use of herbs is seen as an important part of the culture in some communities (3). There is a general belief that herbal medicines are natural and without adverse effects. This has contributed to the increase in the patronage of herbal formulations (4). This popular belief has been proven otherwise (5;6).

Herbal liquors such as Baby Oku, Orijin Bitters, Bajinotu, Aleko, Alomo, 1960 among others have become a common sight in many Nigerian homes, markets, streets and commercial motor parks. Most of these herbals have acclaimed

* Corresponding author: Eniola Bolawa
Biochemistry Department, University Of Lagos, College Of Medicine, Idi-Araba, Lagos State, Nigeria.

medicinal benefits but without empirical data to support these medicinal claims. However, recent studies have showed the need to test some of these herbal liquor mixtures so as to ascertain their safety limits (7).

In Nigeria, one of the most easily accessible forms of medicinal herbs is called 'paraga' with different synonyms such as Opa eyin, Awopa, Jedi and Ewe dongoyaro. Paraga is an herbal mixture with different ingredients and high alcoholic content. It is very popular in many neighborhoods in Nigeria and its usually used as a stimulant. It is assumed to have curative effects on different types of ailment. It is commonly sold by vendors in motor parks where commercial drivers and motorcyclists have easy access to them (8).

In developing countries, there are lots of unregistered and poorly regulated herbal products freely sold in the market with no restraint. There is usually improper use and unrestrained intake leading to severe poisoning and acute health problems. In developing countries, herbal medicines and related products are introduced into the market without any mandatory safety or toxicological evaluation.

Herbs have been shown to produce lots of adverse reactions leading to serious injuries, life-threatening conditions, and even death. Numerous cases of poisoning due to herbal liquors have been reported (9).

The objective of this study was to determine the histopathological effects of herbal liquors on certain organs as well as to measure the extent of strand breaks using *in vivo* alkaline comet assay to detect DNA damage in rats exposed to herbal liquors.

2. Material and methods

2.1. Experimental animals

One hundred and five female Wistar rats with weight between 135 and 200 g were obtained from the Animal Centre at the College of Medicine, University of Lagos, Lagos, Nigeria. The Wistar rats were housed in animal cages in a well-ventilated experimental room with a 12 hr light/12 hr dark cycle. The rats were allowed to acclimatize for a period of 14 days before the commencement of treatments. The rats had free access to standard rat chow and clean water *ad libitum*. The protocol used in this study was approved by the Experimentation Ethics Committee on Animal Use of the College of Medicine, University of Lagos, Lagos, Nigeria.

2.2. Herbal liquors

The herbal liquors under study, Orijin Bitters, Baby Oku, Kummerling Herbal liqueur, 1960 Alcoholic Bitters, Adonko Alcoholic Bitters, Action Bitters, Alomo Bitters, Bajinotu Poka Alcoholic drink, Aleko, Okiki Ibile, Opa Eyin, Ewe Dongoyaro, Jedi and Awopa were purchased from an alcohol store in Mushin market Lagos, Nigeria. These herbal liquors were used as aqueous preparation. Dose selection was premised on the manufacturer's recommendation for the consumption of 70 kg human.

2.3. Experimental design

The one hundred and five female Wistar rats were randomly distributed into fifteen groups of seven rats. At the start of the treatment, group 1-14 rats were administered daily with 0.2ml of the herbal liquor orally using oesophagus cannula from 8:00 to 8.30 am. The different groups are shown below. The control group received distilled water. However, due to high mortality rate in some experimental group, the herbal liquor was diluted with equal amounts of water and the rats were administered 0.1ml of the herbal liquors. Animals were weighed weekly and the treatment lasted for 6 weeks (44 days).

The different groups of rats and the types of herbal liquors administered to them

GROUPS	HERBAL LIQUORS
Group 1	Orijin Bitters
Group 2	Baby Oku
Group 3	Kummerling
Group 4	1960
Group 5	Adonko Alcoholic Bitters
Group 6	Action Bitters
Group 7	Alomo Bitters
Group 8	Bajinotu Poka
Group 9	Aleko
Group 10	Okiki Ibile
Group 11	Opa Eyin
Group 12	Ewe Dongoyaro
Group 13	Jedi
Group 14	Awopa
Group 15	Control

2.4. Blood and organs collection

At the end of treatments, the rats were fasted overnight. They were sacrificed via cervical dislocation. Blood samples were collected into EDTA bottle. Thereafter, the heart, liver, kidney, lung, ovary, brain and muscle were excised, washed in saline and fixed in 10% buffered neutral formalin for histopathology evaluation.

2.5. Histopathology examination

The rat liver, kidney, lung, ovary, heart, brain and muscle for each of the experimental group was fixed in 10% buffered neutral formalin (BNF) immediately following excision from animals. Fixed tissues were subsequently processed for histopathology examinations. Tissues were sectioned at 5 mm thickness and stained with hematoxylin and eosin (H&E) for microscopic evaluation.

2.6. Comet assay

The comet assay was performed as described here (10). The Principle of alkaline comet assay is based on treatment of agarose-embedded cells (lymphocytes) with hypertonic lysis solution and non-ionic detergent which removes their cell membranes, cytoplasm, nucleoplasm and dissolves nucleosomes. Subsequently, when the leftover nucleoid is treated with high alkaline solution, DNA supercoils unwind/ relax thereby exposing the alkali labile sites (apurinic/ apyrimidinic sites) which appear as breaks. Such breaks migrate towards the anode when exposed to current during electrophoresis thereby producing a 'comet'-like appearance. The comet assay, under alkaline conditions (pH >13) can detect DNA strand breaks.

2.6.1. Chemical Reagents

Agarose-normal melting, agarose-low melting, sodium chloride, potassium chloride, disodium hydrogen phosphate, potassium dihydrogen phosphate, disodium ethylenediaminetetraacetic acid (disodium EDTA), tris, sodium hydroxide, sodium dodecyl sulphate / sodium lauryl sarcosinate, triton X 100, trichloro acetic acid, zinc sulphate, glycerol, sodium carbonate, silver nitrate, ammonium nitrate, silicotungstic acid, formaldehyde and lymphocyte.

2.6.2. Preparations of reagent

- Phosphate buffered saline (PBS) was prepared by weighing 8.0g of sodium chloride, 0.2g of potassium chloride, 0.25g of potassium dihydrogen phosphate, 1.44g of disodium hydrogen phosphate and it was dissolved in 800 ml of double-distilled water. pH was adjusted to 7.4 and made up to 1000 ml. The solution was autoclaved and stored at room temperature.
- 0.5% w/v low melting point agarose was prepared by adding 125 mg of low melting point agarose (LMPA) to 25 ml of phosphate buffered Saline (PBS) in a 100ml conical flask. The mouth of the conical flask was sealed with aluminium foil and LMPA was melted in a microwave oven at low power for 1-2 min.
- 0.75% w/v normal melting point agarose was prepared by adding 188 mg of normal melting point agarose (NMPA) to 25 ml of phosphate buffered saline (PBS) in a 100-ml beaker. The mouth of the conical flask was sealed with aluminium foil and NMPA was melted in a microwave oven at low power for 1-2 min.
- The lysis stock solution was prepared by adding 146.1g of sodium chloride, 37.2g of disodium EDTA and 1.2g of tris to 890 ml of double distilled water and stirred till dissolved. 12 g of sodium hydroxyl pellets was added to the mixture and stirred once again. When dissolved completely, 10 g of sodium lauryl sarcosinate was added and stirred once again. The pH was set to 10 and the final volume was adjusted to 890 ml with double-distilled water. The solution was filtered and stored at room temperature.
- For the working lysis solution, 108 ml of stock lysis solution was added to 1.6 ml of tris. The solution was cooled in a refrigerator for 40-60 min prior to use.
- The electrophoresis buffer Stock Solution I was prepared by dissolving 200 g of sodium hydroxide in 500 ml of double-distilled water.
- The electrophoresis buffer Stock Solution II was prepared by dissolving 14.89 g of disodium EDTA in 200 ml of double-distilled water and the pH was adjusted to 10 with sodium hydroxide.
- The electrophoresis working solution was prepared by taking 30 ml of Stock solution I and 5 ml of Stock solution II, it was mixed together and the volume was adjusted to 1000 ml of cold double distilled water.
- Neutralization buffer was prepared by dissolving 48.5 g of tris in 800 ml of double-distilled water. pH was adjusted to 7.5 with concentrated hydrochloric acid and the final volume was adjusted to 1000 ml.

2.6.3. Preparation of reagents for silver staining

- Fixative solution was prepared by dissolve 75 g of trichloroacetic acid, 25 g zinc of sulphate and 25 g of glycerol in 400 ml of double-distilled water and the solution was stirred for 20-30 min. The final volume was adjusted to 500 ml.
- The Staining solution A was prepared by dissolving 25 g of sodium carbonate in 500 ml of double-distilled water by constant stirring for 20-30 min.
- The Staining solution B was prepared by dissolving 100 mg of ammonium nitrate, 100 mg of silver nitrate, 500 mg of silicotungstic acid and 250 µl of formaldehyde in 500 ml of double-distilled water.
- The Stopping solution (1% v/v glacial acetic acid) was prepared by making one ml of glacial acetic acid to 100 ml with double distilled water.

2.6.4. Separation of lymphocyte

2 ml of lymphocyte separation media was added to 2 ml of whole blood by overlaying without mixing together in a centrifuge tube. It was then centrifuged at 1500 RPM for 30 min at room temperature. At the end of 30 min, buffy coat containing peripheral blood mononuclear cells at the interphase between plasma and lymphocyte separation media was aspirated using pasture pipette into a 1.5ml micro-centrifuge tube.

2.6.5. Slide preparation and coating of agarose gel

Plain grease-free, clean microscope slides were used for layering the gels. The slides were labelled accordingly.

100 µl of hot 0.75% NMPA was pipetted and dropped over one end of the slide. It was smeared onto the opposite direction with the help of another plain slide inclined at about 45° angle and the slides were allowed to dry at 37° C.

After NMPA was solidified, 60 μ l of LMPA was added to 20 μ l of lymphocyte in a micro-centrifuge tube and was mixed thoroughly. The lymphocyte-LMPA gel mixture was pipetted and dropped over the NMPA layer. A cover slip is carefully placed over the gel so that it forms a uniform layer over the NMPA coat, making sure to avoid air bubbles. The gel was allowed to solidify at 4 °C in a refrigerator for 10-15 min.

After the lymphocyte-LMPA cell layer has solidified, the cover slip was carefully removed. 75 μ l of LMPA was added onto the agarose gel mixture layer and a fresh cover slip was carefully placed over the gel mixture layer while avoiding air bubbles. The gel was allowed to solidify at 4 °C in a refrigerator for 10-15 min.

After the third layer of agarose gel was solidified, the cover slip was carefully removed again and the slides were gently immersed into staining trough containing cold lysis solution and refrigerated for minimum 1 hour.

The alkaline unwinding and electrophoresis of slides was carried after lysis at 4°C, the slides were gently removed from the lysis solution and placed exactly perpendicular to both the electrodes with the agarose-coated side facing upwards in horizontal submarine gel electrophoresis system. The electrophoresis tank is filled with fresh cold pH > 13 electrophoresis buffer until the buffer completely covers the slides without formation of air bubbles over the agarose gel. The slides were allowed to stay in the alkaline buffer for 30 min in order to unwind DNA strands and expose the alkali labile sites (alkali unwinding). Power supply was turned on with 0.74 V/ cm (between electrodes) and current is adjusted to 300mA by raising or lowering the buffer level. Electrophoresis was carried out for 30 min.

After electrophoresis, the slides were gently lifted from the electrophoresis buffer and placed on a staining tray. The slides were carefully flooded with neutralizing tris buffer (pH7.4) for 5 min and the buffer was drained, the process was repeated two more times followed by several washes with distilled water.

After electrophoresis and neutralization the gel slides were dried overnight.

The slides were placed in a fixative solution for 10 min and washed several times with distilled water. The slides were allowed to dry at 37°C for at least 1 h to a maximum of overnight before staining.

The staining of slides was carried out by placing the slides inside a staining box. 32 ml of staining solution A and 68 ml of staining solution B were simultaneously poured gently over the slides. The staining box was closed with the lid and kept on a platform rocker which was set at a slow speed for 10-20 min to ensure uniform staining. This step was repeated three times with fresh staining Solution A and Solution B until a grayish colour develops on the slides. The slides were then transferred to a tray containing the stopping solution for about 5 min or until a yellowish-brown colour develops. The slides were washed with distilled water and allowed to dry completely in an inclined position at room temperature.

2.6.6. Comet visualization and scoring

The slides stained with silver nitrate were observed under a light microscope and images were captured using charged coupled device (CCD) camera.

CometScore pro image analysis software was used to measure all parameters for the cell which includes Comet length, comet height, comet area, comet intensity, comet mean intensity, head diameter, head area, head intensity, head mean intensity, %DNA in head, tail length, tail area, tail intensity, tail mean intensity, %DNA in tail, tail moment and olive moment.

2.6.7. Statistical analysis

All data are presented as the mean \pm standard deviation. Data were subjected to statistical analysis using the one-way ANOVA (GraphPad Software Inc., San Diego, CA). Differences among the group means were evaluated by Dunnett's multiple comparisons test. Mean values were considered to be statistically significant at $P < 0.05$.

3. Results

3.1. Histopathology Results

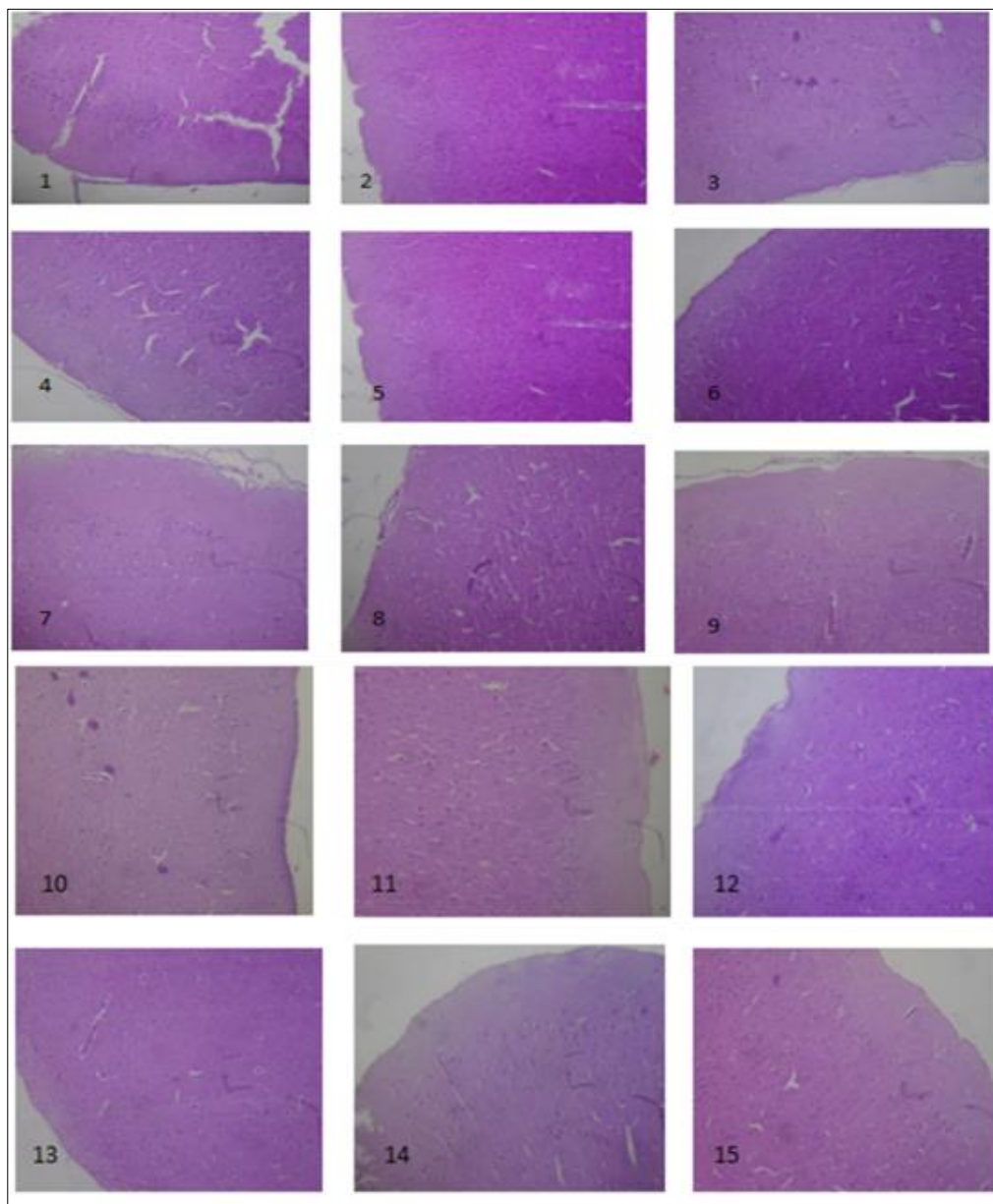


Figure 1 Photomicrograph sections of the brain in rats exposed to herbal liquors. The histologic section of brain tissue show neuronal cells on a background of neuropil. No abnormalities were seen in brain of the rats

1. Brain tissues of rats administered with Orijin Bitters (herbal liquor) showing no abnormalities
2. Brain tissues of rats administered with Baby Oku (herbal liquor) showing no abnormalities
3. Brain tissues of rats administered with Kummerling (herbal liquor) showing no abnormalities
4. Brain tissues of rats administered with 1960 (herbal liquor) showing no abnormalities
5. Brain tissues of rats administered with Adonko (herbal liquor) showing no abnormalities
6. Brain tissues of rats administered with Action Bitters(herbal liquor) showing no abnormalities
7. Brain tissues of rats administered with Alomo Bitters (herbal liquor) showing no abnormalities
8. Brain tissues of rats administered with Bajinotu Poka (herbal liquor) showing no abnormalities
9. Brain tissues of rats administered with Aleko (herbal liquor) showing no abnormalities
10. Brain tissues of rats administered with Okiki Ibile (herbal liquor) showing no abnormalities

11. Brain tissues of rats administered with Opa Eyin (herbal liquor) showing no abnormalities
12. Brain tissues of rats administered with Ewe Dongoyaro (herbal liquor) showing no abnormalities
13. Brain tissues of rats administered with Jedi (herbal liquor) showing no abnormalities
14. Brain tissues of rats administered with Awopa (herbal liquor) showing no abnormalities
15. Brain tissues of rats in the Control group, showing no abnormalities.

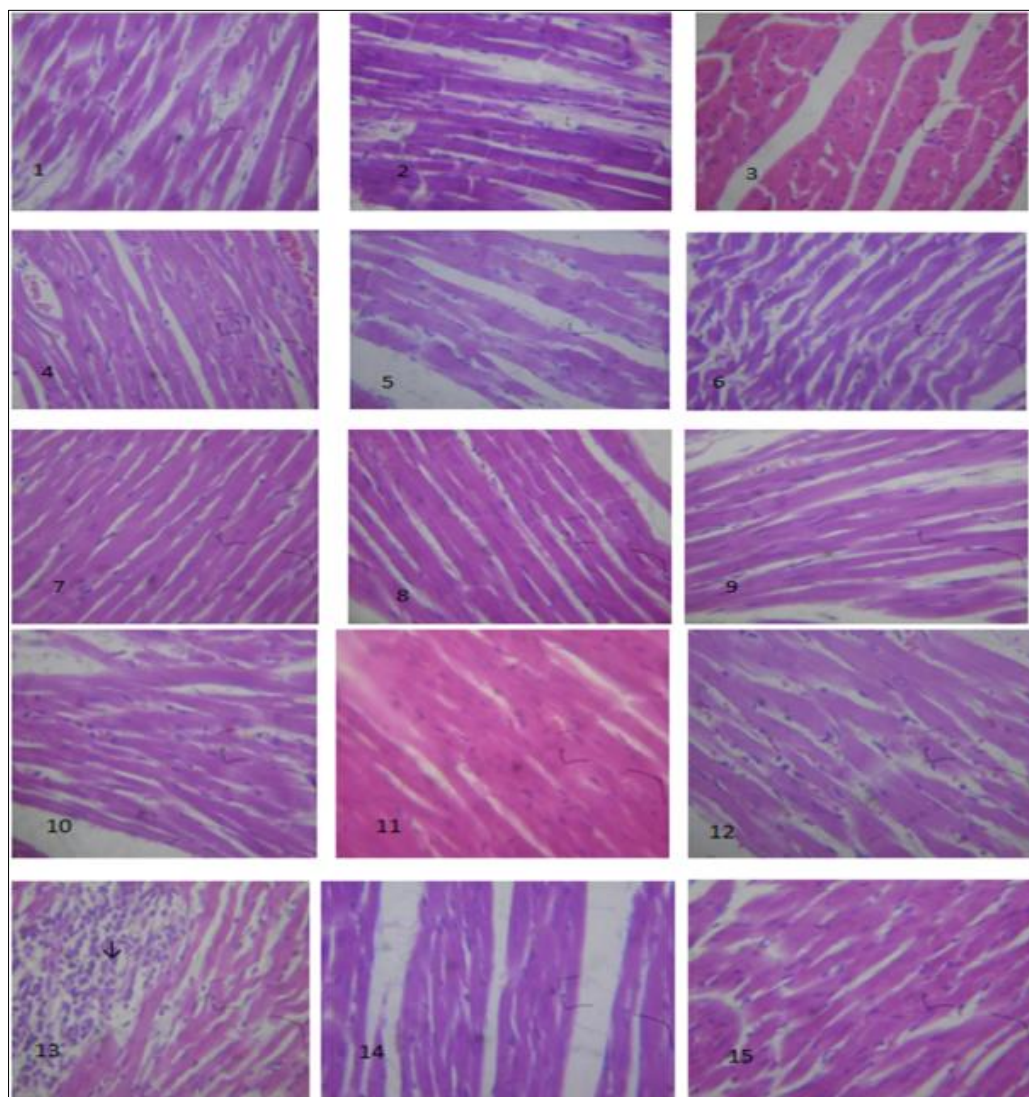


Figure 2 Photomicrograph sections of the heart in rats exposed to herbal liquors. The histologic sections of heart muscle show interlacing fascicles of cardiac myocytes/ myocardial cells

1. Heart tissues of rats administered with Orijin Bitters (herbal liquor) showing no abnormalities
2. Heart tissues of rats administered with Baby Oku (herbal liquor) showing no abnormalities
3. Heart tissues of rats administered with Kummerling (herbal liquor) showing no abnormalities
4. Heart tissues of rats administered with 1960 (herbal liquor) showing no abnormalities
5. Heart tissues of rats administered with Adonko (herbal liquor) showing no abnormalities
6. Heart tissues of rats administered with Action Bitters(herbal liquor) showing no abnormalities
7. Heart tissues of rats administered with Alomo Bitters (herbal liquor) showing no abnormalities
8. Heart tissues of rats administered with Bajinotu Poka (herbal liquor) showing no abnormalities
9. Heart tissues of rats administered with Aleko (herbal liquor) showing no abnormalities
10. Heart tissues of rats administered with Okiki Ibile (herbal liquor) showing no abnormalities
11. Heart tissues of rats administered with Opa Eyin (herbal liquor) showing no abnormalities
12. Heart tissues of rats administered with Ewe Dongoyaro (herbal liquor) showing no abnormalities

13. Heart tissues of rats administered with Jedi (herbal liquor) showing dense aggregates of chronic inflammatory cell infiltrates (myocardial cells).
14. Heart tissues of rats administered with Awopa (herbal liquor) showing no abnormalities
15. Heart tissues of rats in the Control group, showing no abnormalities

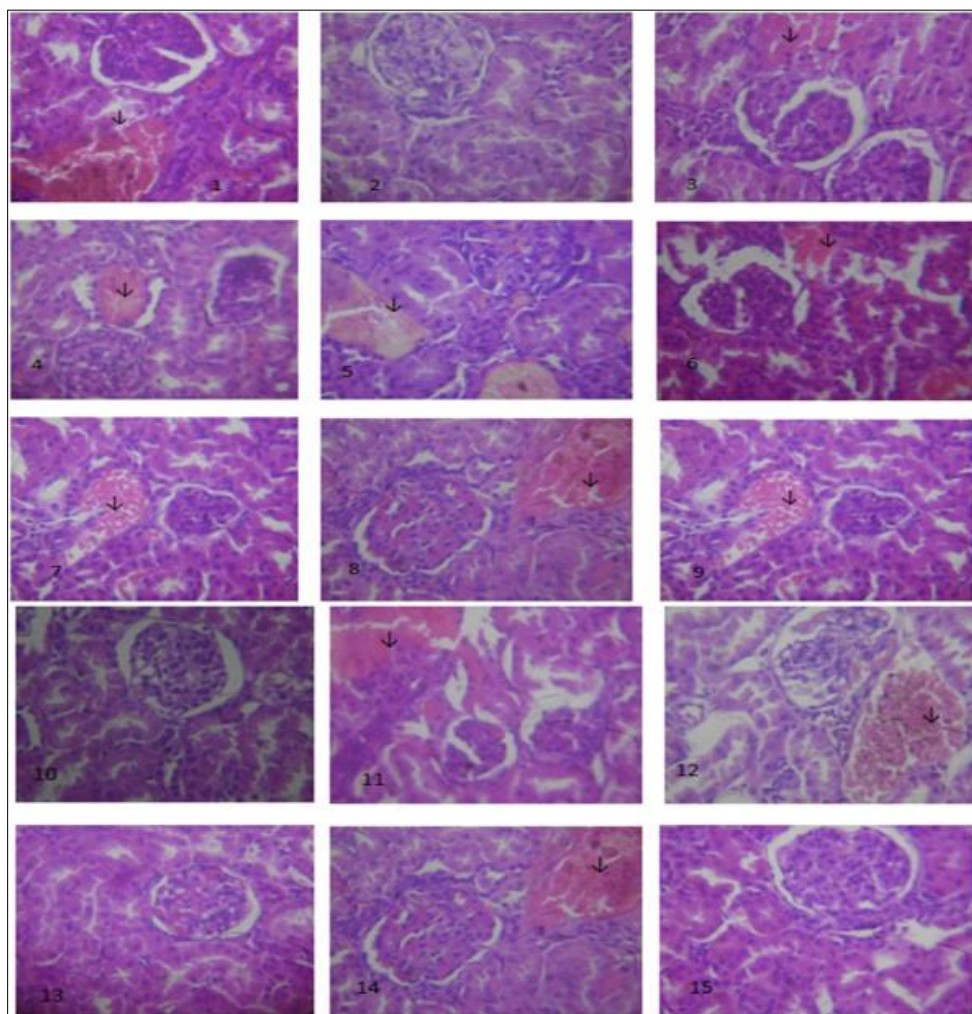


Figure 3 Photomicrograph sections of the kidneys in rats exposed to herbal liquors. The histologic sections of kidney tissues show normocellular glomerular tufts disposed on a background containing renal tubules

1. Kidney tissues of rats administered with Orijin Bitters (herbal liquor) showing congested vessels with vascular congestion in the kidneys
2. Kidney tissues of rats administered with Baby Oku (herbal liquor) showing no abnormalities
3. Kidney tissues of rats administered with Kummerling (herbal liquor) showing congested vessels with vascular congestion in the kidneys.
4. Kidney tissues of rats administered with 1960 (herbal liquor) showing congested vessels with vascular congestion in the kidneys.
5. Kidney tissues of rats administered with Adonko (herbal liquor) showing congested vessels with vascular congestion in the kidneys.
6. Kidney tissues of rats administered with Action Bitters(herbal liquor) showing congested vessels with vascular congestion in the kidneys.
7. Kidney tissues of rats administered with Alomo Bitters (herbal liquor) showing congested vessels with vascular congestion in the kidneys.
8. Kidney tissues of rats administered with Bajinotu Poka (herbal liquor) showing congested vessels with vascular congestion in the kidney

9. Kidney tissues of rats administered with Aleko (herbal liquor) showing congested vessels with vascular congestion in the kidneys.
10. Kidney tissues of rats administered with Okiki Ibile (herbal liquor) showing no abnormalities
11. Kidney tissues of rats administered with Opa Eyin (herbal liquor) showing congested vessels with vascular congestion in the kidneys.
12. Kidney tissues of rats administered with Ewe Dongoyaro (herbal liquor) showing congested vessels with vascular congestion in the kidneys.
13. Kidney tissues of rats administered with Jedi (herbal liquor) showing no abnormalities
14. Kidney tissues of rats administered with Awopa (herbal liquor) showing congested vessels with vascular congestion in the kidneys.
15. Kidney tissues of rats in the Control group, showing no abnormalities

(↓) sign indicates congested vessels showing vascular congestion in the kidneys.

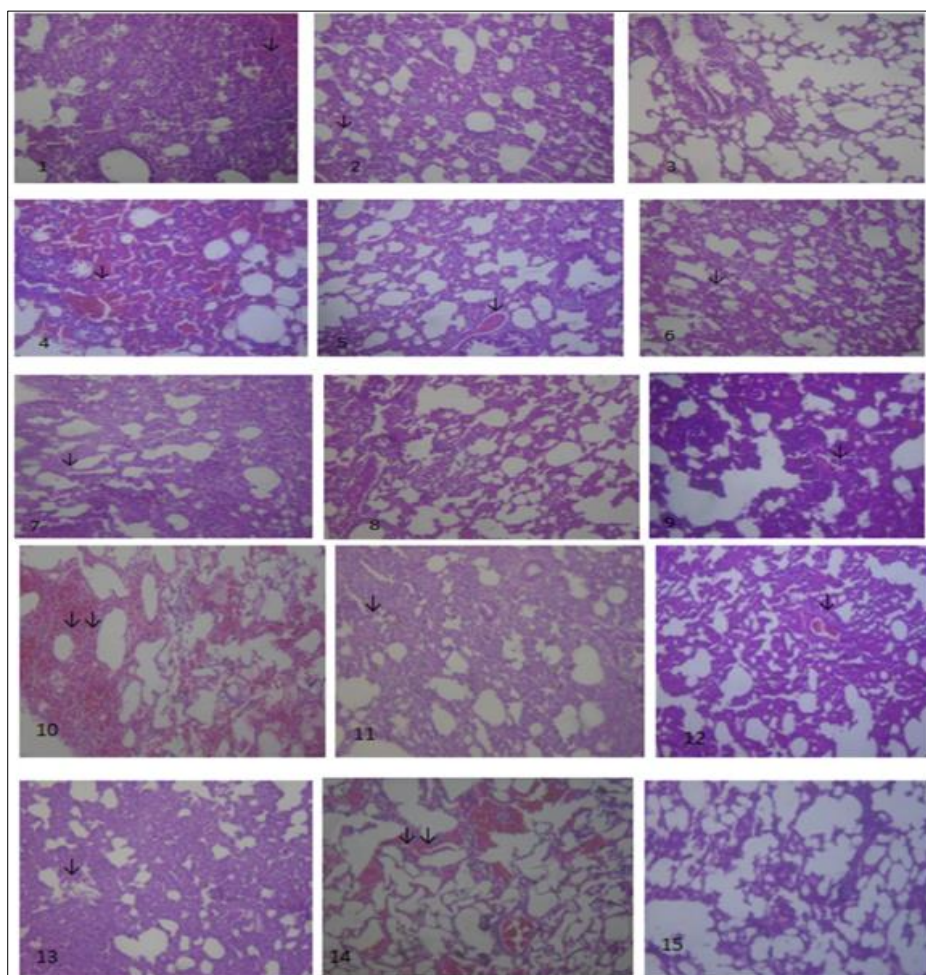


Figure 4 Photomicrograph sections of the lung in rats exposed to herbal liquors

1. Lung tissues of rats administered with Orijin Bitters (herbal liquor) showing moderate to severe pulmonary inflammation.
2. Lung tissues of rats administered with Baby Oku (herbal liquor) showing moderate to severe pulmonary inflammation.
3. Lung tissues of rats administered with Kummerling (herbal liquor) showing no abnormalities
4. Lung tissues of rats administered with 1960 (herbal liquor) showing moderate to severe pulmonary inflammation.

5. Lung tissues of rats administered with Adonko (herbal liquor) showing moderate to severe pulmonary inflammation.
6. Lung tissues of rats administered with Action Bitters(herbal liquor) showing moderate to severe pulmonary inflammation.
7. Lung tissues of rats administered with Alomo Bitters (herbal liquor) showing moderate to severe pulmonary inflammation.
8. Lung tissues of rats administered with Bajinotu Poka (herbal liquor) showing normal tissues
9. Lung tissues of rats administered with Aleko (herbal liquor) showing moderate to severe pulmonary inflammation.
10. Lung tissues of rats administered with Okiki Ibile (herbal liquor) showing severe congestion of pulmonary vessels and interstitial haemorrhages
11. Lung tissues of rats administered with Opa Eyin (herbal liquor) showing moderate to severe pulmonary inflammation.
12. Lung tissues of rats administered with Ewe Dongoyaro (herbal liquor showing moderate to severe pulmonary inflammation.
13. Lung tissues of rats administered with Jedi (herbal liquor showing moderate to severe pulmonary inflammation.
14. Lung tissues of rats administered with Awopa (herbal liquor) showing severe congestion of pulmonary vessels and interstitial haemorrhages
15. (15)Lung tissues of rats in the Control group, showing no abnormalities
16. (↓) sign shows the histologic sections of the lung tissue with reduction in air filled alveolar spaces with infiltration of alveoli and interstitium by aggregates of inflammatory cells indicating moderate to severe pulmonary inflammation.
17. (↓↓) signs indicate congestion of pulmonary vessels and interstitial haemorrhages.

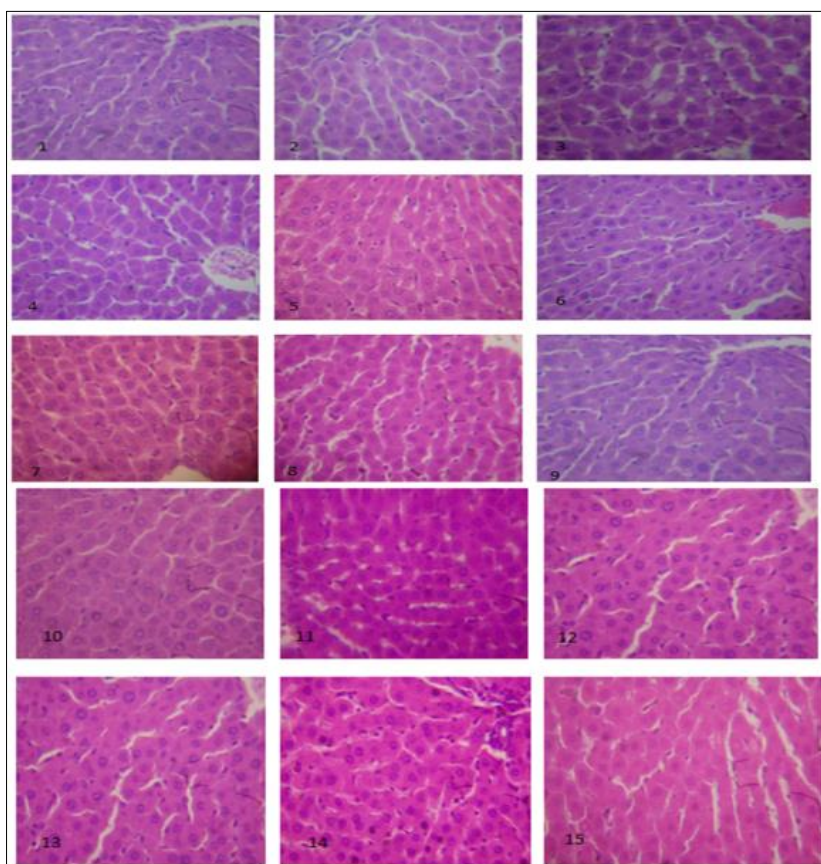


Figure 5 Photomicrograph sections of the liver in rats exposed to herbal liquors. The histologic sections of liver tissue show parallel radially arranged plates of hepatocytes.

No abnormalities are seen in the liver of the rat test groups.

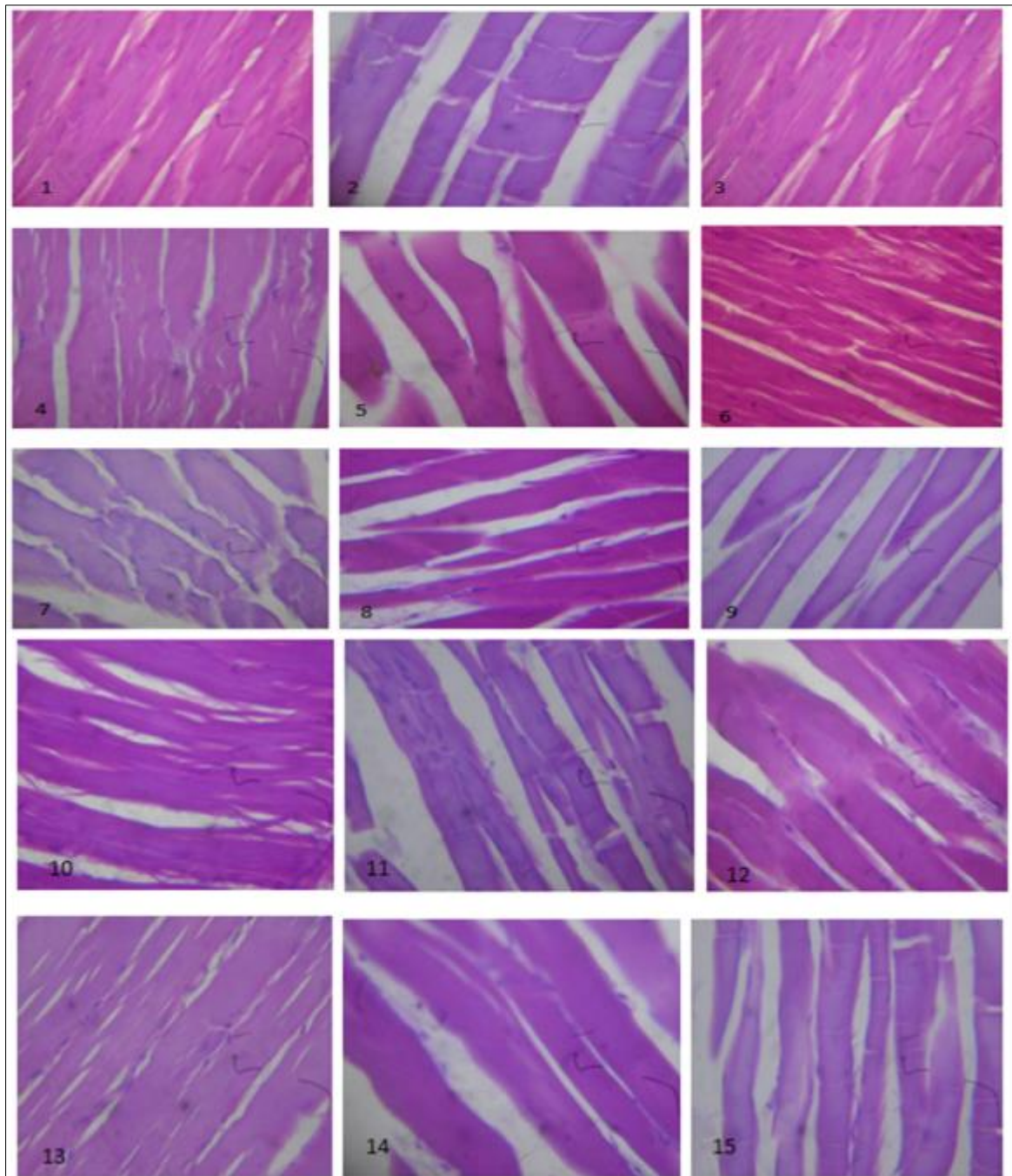


Figure 6 Photomicrograph sections of the muscle in rats exposed to herbal liquors. The histologic section of tissue shows parallel fascicles of skeletal muscle myocytes. No abnormalities are seen in the muscle of the rat test groups

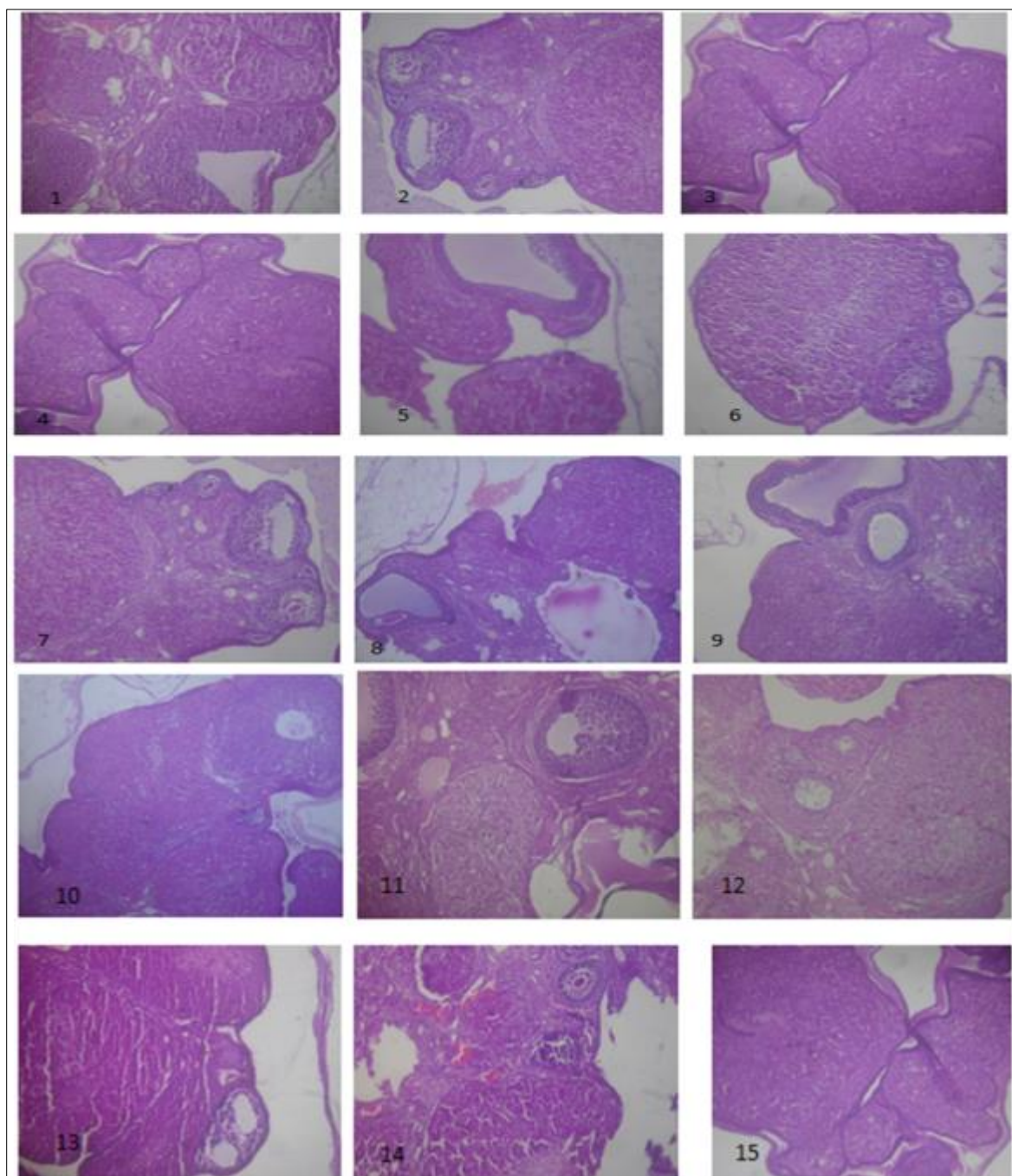

Figure 7 Photomicrograph sections of the ovaries in rats exposed to herbal liquors. The histologic sections of ovarian tissue show follicles at varying stages of development and corpora lutea (indicating ovulation). No abnormalities are seen in the ovaries of the rat test groups

3.2. Comet assay results

3.2.1. The result of % DNA in tail analysis on herbal liquors

The % DNA in Tail (Fig. 8.0) shows that there is statistically significant difference in the mean \pm standard deviation in all the herbal liquors used in this study when compared with the control which had a value of 0. The mean \pm standard deviation observed in the herbal liquors was as follows: Orijin Bitters (15.17 ± 0.07662), Baby Oku (2.048 ± 0.04658), Kummerling (10.55 ± 0.02646), 1960 (2.434 ± 0.03912), Adonko (1.87 ± 0.03391), Action Bitters (0.758 ± 0.02387), Alomo Bitters (0.932 ± 0.01924), Bajinotu Poka (3.948 ± 0.03701), Aleko (0.578 ± 0.04658), Okiki Ibile (3.36 ± 0.3286), Opa Eyin (0.88 ± 0.03317), Ewe Dongoyaro (4.852 ± 0.03271), Jedi (11.2 ± 0.4359), Awopa (2.454 ± 0.02881).

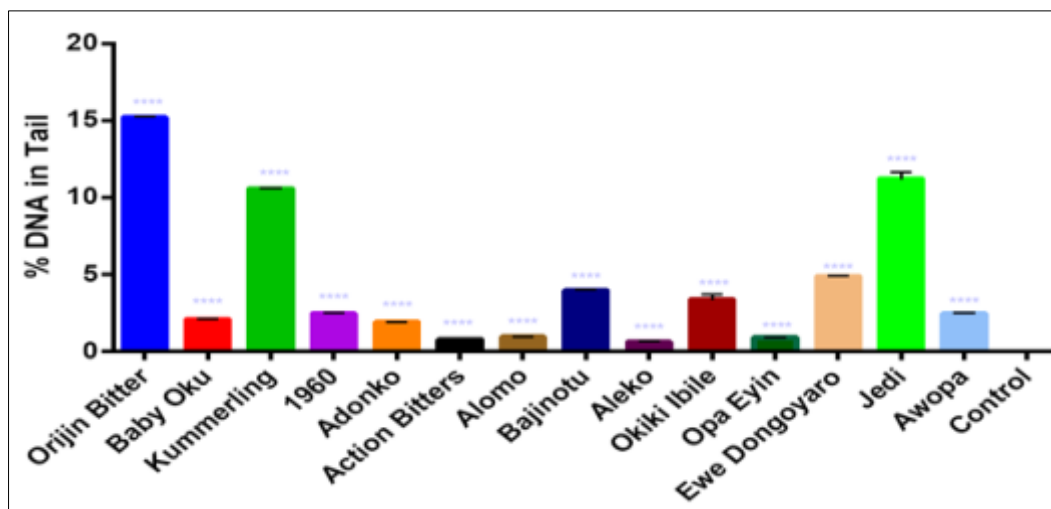


Figure 8 % DNA in Tail of rat lymphocytes exposed to herbal liquors using comet assay. Data are expressed as the mean \pm SD. A value of $*P < 0.05$ was considered statistically significant

3.2.2. The result of % DNA in head analysis on herbal liquors

The % DNA in head (Fig. 9.0) shows that there is statistically significant difference in the mean \pm standard deviation in the herbal liquors used in this study when compared with the control which had a value of 100. The mean \pm standard deviation observed in the herbal liquors was as follows: Orijin Bitters (84.83 ± 0.6177), Baby Oku (97.952 ± 0.5836), Kummerling (89.45 ± 0.3354), 1960 (97.566 ± 0.4392), Adonko (98.13 ± 0.1378), Action Bitters (99.242 ± 4.545), Alomo Bitters (99.068 ± 0.1431), Bajinotu Poka (96.052 ± 0.1408), Aleko (99.422 ± 0.1342), Okiki Ibile (96.64 ± 0.5813), Opa Eyin (99.12 ± 4.012), Ewe Dongoyaro (95.148 ± 0.1641), Jedi (88.8 ± 0.4092), Awopa (97.546 ± 0.5156).

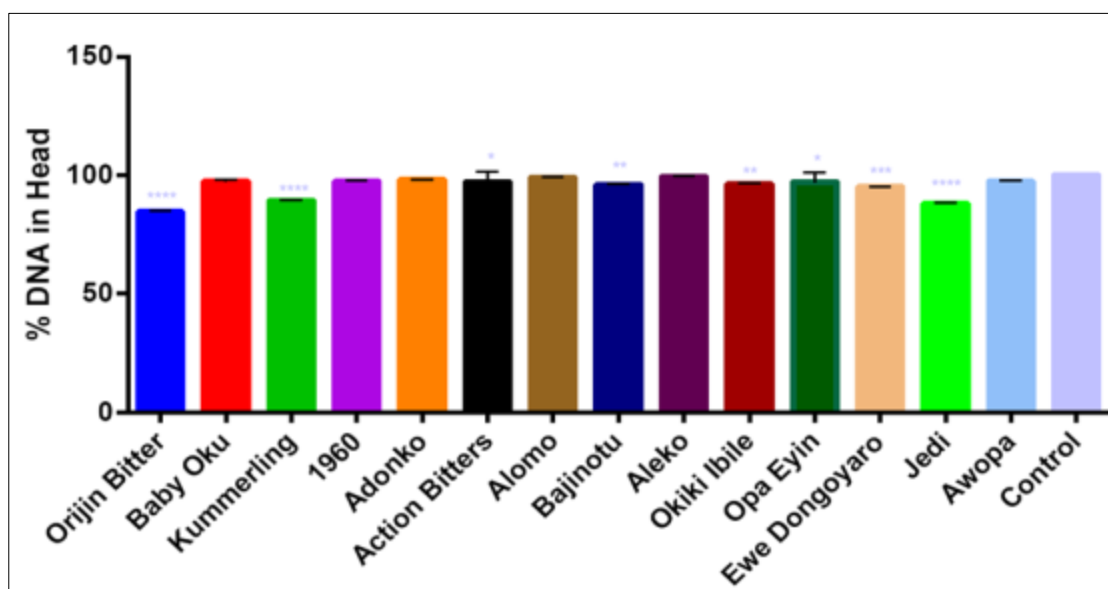


Figure 9 % DNA in Head of rat lymphocytes exposed to herbal liquors using comet assay. Data are expressed as the mean \pm SD. A value of $*P < 0.05$ was considered statistically significant

3.2.3. The result of olive moment analysis on herbal liquors

The olive moment (Figure 10.0) shows that there is statistically significant difference in the mean \pm standard deviation in all the herbal liquors used in this study when compared with the control which had a value of 0. The mean \pm standard deviation observed in the herbal liquors was as follows: Orijin Bitters (12.27 ± 0.001516), Baby Oku (0.41487 ± 0.001304), Kummerling (6.093 ± 0.002236), 1960 (0.5954 ± 0.004561), Adonko (0.7356 ± 0.002702), Action Bitters (0.1842 ± 0.003114), Alomo Bitters (0.3032 ± 0.003033), Bajinotu Poka (1.328 ± 0.002608), Aleko (0.2234 ± 0.002408),

Okiki Ibile (0.5276 ± 0.004037), Opa Eyin (0.0758 ± 0.002775), Ewe Dongoyaro (3.154 ± 0.003162), Jedi (5.143 ± 0.001871), Awopa (0.2924 ± 0.00305).

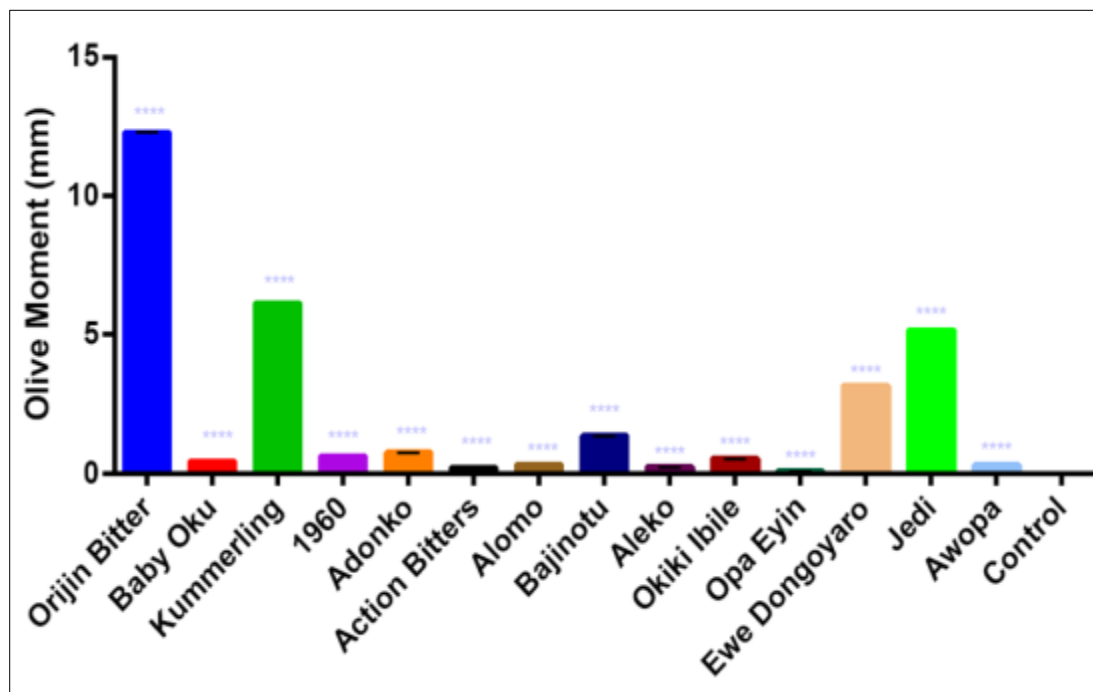


Figure 10 Olive moment of rat lymphocytes exposed to herbal liquors using comet assay. Data are expressed as the mean \pm SD. A value of $*P < 0.05$ was considered statistically significant

3.2.4. The result of tail length analysis on herbal liquors

The tail length (Fig. 11.0) shows that there is statistically significant difference in the mean \pm standard deviation in the herbal liquor Orijin Bitters (71.8 ± 3.114), Baby Oku (1.033 ± 0.8386), Kummerling (48.4 ± 3.507), 1960 (0.75 ± 0.336), Adonko (0.8 ± 0.2828), Action Bitters (1.5 ± 0.7071), Alomo (0.75 ± 0.3536), Bajinotu (10.6 ± 1.517), Aleko (38.8 ± 2.28), Okiki Ibile (10 ± 2.739), Opa Eyin (2.2 ± 1.095), Ewe Dongoyaro (57.2 ± 1.924) and Jedi (10.2 ± 1.483), Awopa (1.5 ± 0.7071) when compared with the control with a value of 0.

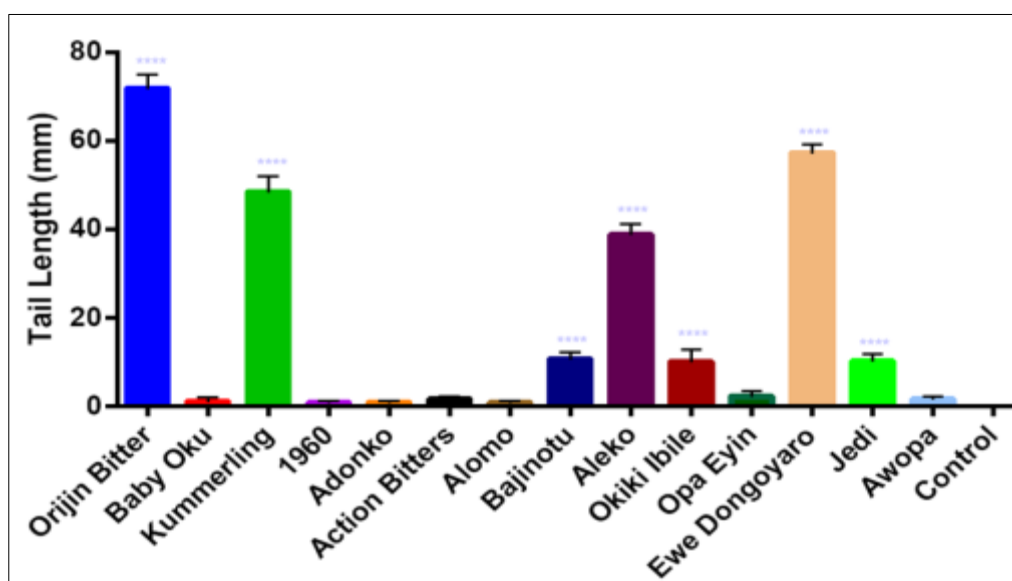


Figure 11 Tail length of rat lymphocytes exposed to herbal liquors using comet assay. Data are expressed as the mean \pm SD. A value of $*P < 0.05$ was considered statistically significant

3.2.5. The result of tail moment analysis on herbal liquors

The tail moment (Fig. 12.0) shows that there is statistically significant difference in the mean \pm standard deviation in the herbal liquor Orijin Bitters (10.89 ± 0.47720), Kummerling (5.107 ± 0.3796), 1960 (0.0074 ± 0.01113), Adonko (0.2222 ± 0.4863), Action Bitters (0.3306 ± 0.6992), Alomo Bitters (0.0278 ± 0.04154), Bajinotu Poka (0.418 ± 0.05624), Aleko (0.2236 ± 0.00658), Okiki Ibile (0.3356 ± 0.09071), Opa Eyin (0.0358 ± 0.0319), Ewe Dongoyaro (2.775 ± 0.07986), Jedi (1.142 ± 0.1555), Awopa (0.01488 ± 0.02218) when compared with the control with a value of 0.

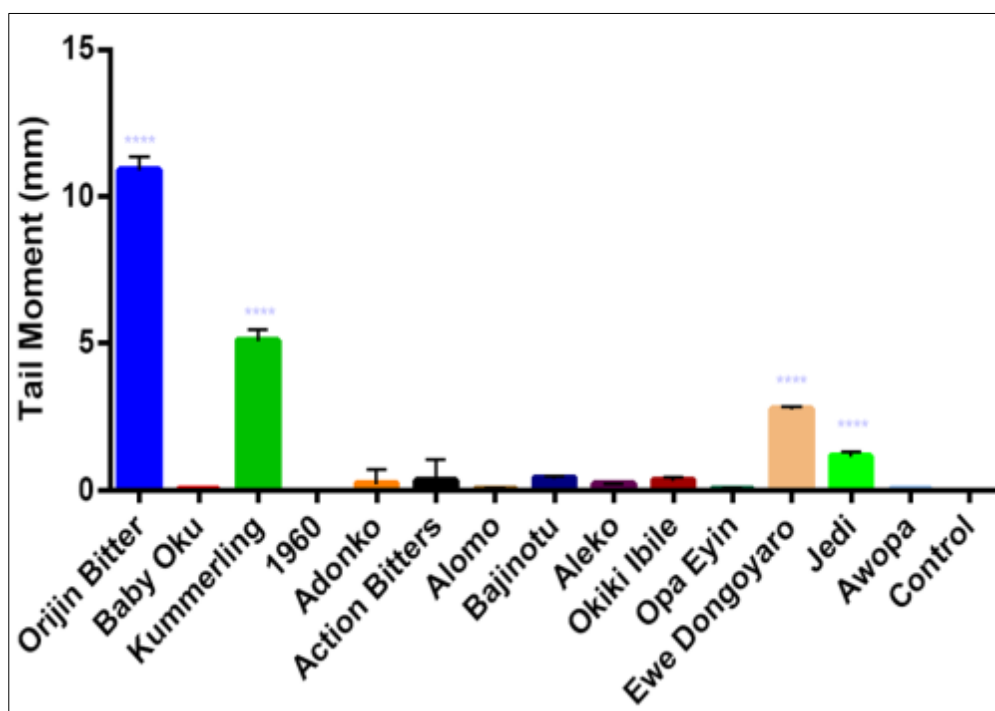


Figure 12 Tail moment of rat lymphocytes exposed to herbal liquors using comet assay. Data are expressed as the mean \pm SD. A value of $*P < 0.05$ was considered statistically significant

4. Discussion

The metabolism of alcohol produces reactive oxygen species (ROS) which is detrimental to the cellular antioxidant defence system and can also cause cellular injury (11). The body responds to acute administration of alcohol by generating oxygen-derived free radicals resulting in alterations in the cardiac muscle (12). Alcohol abuse is a risk factor to various cardiovascular diseases, digestive tract disorders, and cancers (13). It has been shown to interfere with a number of myocardial metabolic steps and other cellular mechanisms (14). The cardiovascular system is a major target for ROS which plays an important role in the cause of cardiac toxicity in chronically ethanol-intoxicated animals (12). Many chronic diseases such as acute cardiomyopathy (ACM) and other heart diseases (15; 16), may develop following chronic alcohol ingestion and contribute to alcoholism-related high morbidity and mortality.

In this study, the histopathology examination of rat brain, ovaries, muscle and liver tissues exposed to herbal liquors showed intact and normal cellular architecture in the control group as well as in all the groups administered with herbal liquors. The concentrations of acetaldehyde in the brain are not high enough to produce negative effects, because the brain has a unique barrier that protects it from toxic products circulating in the bloodstream (17).

The histologic sections of the heart muscles in all the groups exposed to herbal liquors revealed no abnormalities in all the test groups except in the heart of the Jedi treated group [Figure 2.0 (13)] where the heart muscle contain dense aggregates of chronic inflammatory cell infiltrates that can lead to myocarditis. In vitro, the overproduction of free radicals leads to the depression of myocardial contractility and causes myocardial tissue injury. It also induces myocyte apoptosis. Reduction of heart anti-oxidative capacity and morphological changes have been reported in animals chronically intoxicated with alcohol (19; 20). Reactive oxygen species, generated from alcohol metabolism, have been shown to play a role in the onset of heart disturbances in ethanol-intoxicated animals (21; 22). The myocarditis observed in the Jedi treated group was in accordance with the findings of some scientists who demonstrated that

chronic ethanol administration in rats caused significant cardiac injury, as observed by histopathological results on the cardiac tissue (23).

The kidney as an excretory organ is known to be central to total body homeostasis, regulating extracellular water and electrolytes as well as acid base balance, among other critical functions. Renal damage could occur as a result of acute intoxication or chronic alcoholism. In this study, the histopathology examination of rat kidneys exposed to the following herbal liquors: Orijin Bitters [Figure 3.0(1)], Kummerling [Figure 3.0(3)], 1960 [Figure 3.0(4)], Adonko [Figure 3.0(5)], Action Bitters [Figure 3.0(6)], Alomo Bitters [Figure 3.0(7)], Bajinotu Poka [Figure 3.0(8)], Aleko [Figure 3.0(9)], Opa Eyin [Figure 3.0(11)], Ewe Dongoyaro [Figure 3.0(12)] and Awopa [Figure 3.0(14)] had congested blood vessels while the control group [Figure 3.0(15)], Baby Oku [Figure 3.0(2)], Okiki Ibile [Figure 3.0(10)] and Jedi group [Figure 3.0(13)] had no abnormalities in their kidneys. The vascular congestion observed in the kidneys of this study was in accordance with the findings of these scientists (24) in which the histopathology results of rat renal sections exposed repeated to Fijk herbal revealed compromised cellular integrity leading to swollen renal tubules, severe nephritis, hypochromic and necrosis. Also, the findings in this publication (25) showed that kidney tissues exposed to moderate ethanol showed sloughing off of cells that line tubules with some ghostlike appearance of the tubules causing acute tubular necrosis. Some scientists reported that moderate ethanol intake leads to expansion of the kidney tissue which is followed by congested glomeruli, mononuclear cellular infiltration which are features of mild nephritis that caused kidney tissue damage (26).

The histological sections of the lung tissue exposed to the herbal liquors Orijin Bitters [Figure 4.0(1)], Baby Oku [Figure 4.0(2)], 1960 [Figure 4.0(4)], Adonko [Figure 4.0(5)], Action Bitters [Figure 4.0(6)], Alomo Bitters [Figure 4.0(7)], Aleko [Figure 4.0(9)], Opa Eyin [Figure 4.0(11)], Ewe Dongoyaro [Figure 4.0(12)] and Jedi [Figure 4.0(13)] in rats revealed the reduction in air filled alveolar spaces with infiltration of alveoli and interstitium by aggregates of inflammatory cells indicating moderate to severe pulmonary inflammation while the histological sections of the lung tissue exposed to Okiki Ibile [Figure 4.0(10)] and Awopa [Figure 4.0(14)] herbal liquors reveals severe congestion of pulmonary vessels and interstitial haemorrhages. However, there were no incidences of morphological lesions in the lungs of the control group [Figure 4.0(15)], Kummerling [Figure 4.0(3)] and Bajinotu Poka [Figure 4.0(8)]. The histopathological findings in this study, supports a previous report (25). where it was observed that there was more lung tissue damage recorded with increase in alcohol consumption. This report is also in agreement with a previous published work, that reported that chronic alcohol consumption, could lead to alcoholic lung disease and also alcoholic lung disease could be comparative to liver disease following the onset of chronic alcohol usage (27).

Mammalian lungs can metabolize ingested ethanol by alcohol dehydrogenase (ADH) followed by acetaldehyde dehydrogenase (ALDH). This is at rates dependent on its concentration (28; 29). Ethanol can also be metabolized by microsomal cytochrome P450 2E1 (CYP2E1) and peroxisomal catalase to acetaldehyde in both the liver and in the brain. CYP2E1 is particularly induced during chronic alcohol abuse and is shown to be responsible for production of free radicals. The pulmonary inflammation observed in this study may be due to the generation of reactive oxygen species in the lungs.

Histopathological sections of the liver (Figure 5.0), muscle (Figure 6.0) and the ovaries (Figure 7.0) revealed only normal cells and no abnormalities. Consumption of the herbal liquors had no effect on the liver, muscle and ovaries.

Preservation of genetic information is of prime importance to all living systems. However, the integrity of the genome is continuously threatened by environmental agents (e.g. the ultraviolet (UV) component of sunlight, ionizing radiation and genotoxic chemicals). DNA damage can lead to mutations. This is a primary step into cancer initiation. DNA damage may also result in cellular malfunction and death and these changes may cause the progressive loss of tissue homeostasis and organismal decline. Oxidative stress, ionizing radiation, UV light and numerous chemicals induce a wide verity of DNA lesions (31). Alcohol metabolism generates potentially genotoxic ROS and acetaldehyde, which have been shown to induce DNA damage, including oxidative modifications, acetaldehyde-derived DNA adducts and crosslinks (32; 33)

The evaluation of endogenous DNA damage using comet assay provides information on the detection of DNA single-strand breaks. In this present study, the comet assay also referred to as alkaline single cell gel electrophoresis was used to detect DNA damage in rats lymphocytes administered with herbal liquors. Strand breaks arise from DNA damage due to oxidative stress.

In this study, the extent of DNA damage was quantified by measuring the displacement of the genetic material between the cell nucleus (comet head) (Figure 9.0) and the resulting 'tail' (Figures 8.0; 11.0 and 12.0). The tail length was used as an index of DNA damage in this study. The tail moment which is a measure of the percentage DNA in the tail multiply

by length of the comet tail in this study showed a significant increase ($p < 0.05$) in the treatment group Orijin Bitters, Kummerling, Ewe Dongoyaro, Jedi when compared with the control. The control group lacked a tail which indicated that DNA was intact. The olive tail moment (Figure 10.0) is the product of the tail length and the fraction of the total DNA in the tail. The olive tail moment shows the amount of DNA breaks in all the test groups, the highest amounts being in the rats treated with Orijin and Jedi herbal liquor.

The % DNA in tail which is used for a measure of the amount of DNA strand break present in the tail in this study (Figure 8.0), showed evidence of DNA strand breaks in all the lymphocytes of all the groups exposed to herbal liquors except the control group which had no tail and indicated an intact DNA. However, the % DNA in head (Figure 9.0) which is used for a measure of the amount of DNA present in the comet head in this study indicated that the lymphocytes of all the groups exposed to herbal liquors had an incomplete DNA in the comet head due to DNA strand breaks. The control group had an intact DNA in the comet head.

The presence of DNA strand breaks in tail length (Figure 11.0), tail moment (Figure 12.0), % DNA in head (Figure 9.0) and the % DNA in tail (Figure 8.0) in the herbal liquors administered in rats clearly shows the relation between alcohol consumption and DNA damage. This result is consistent with previous study in which DNA strand breaks were observed in the tail length and tail moment in ethanol-induced DNA damage by single-cell gel electrophoresis (34). Strand breaks due to DNA damage in lymphocytes of patients with chronic alcoholism have also been reported (35).

The result obtained in this study shows that herbal liquor causes strand breaks in DNA and this may be due to the effect of acetaldehyde in the production of DNA strand breaks which is mediated via the generation of free radicals which attack DNA and leads to cleavage of the DNA backbone.

5. Conclusion

In conclusion, this study reveals that these herbal liquors: Orijin Bitters, Baby Oku, Kummerling, 1960, Adonko, Action Bitters, Alomo Bitters, Bajinotu Poka, Aleko, Okiki Ibile, Opa Eyin, Ewe Dongoyaro, Jedi and Awopa contain substances that produce reactive oxygen species which affects the morphology of the kidneys, heart and lungs due to the vascular congestion, inflammation, pulmonary congestion and hemorrhages observed in the histopathology study. It should be noted that these herbal liquors are found in Nigeria. Also, these toxic substances induce DNA strand breaks that could compromise the integrity of the DNA which can lead to mutation.

Compliance with ethical standards

Acknowledgments

We appreciate the staff of the Central Research Laboratory, University of Lagos and the Nigeria Institute of Medical Research, Yaba, Lagos State, Nigeria, for the use of their laboratories.

Disclosure of conflict of interest

We have no financial or non financial competing interests to report.

Statement of ethical approval

This research work was carried out in total compliance with the guidelines for the ethical conduct in the care and use of nonhuman animals in research.

References

- [1] Ekor M, Adeyemi OS, Otuechere CA. Management of anxiety and sleep disorders: role of complementary and alternative medicine and challenges of integration with conventional orthodox care. *Chinese journal of integrative medicine*. 2013; 19(1): 5-14.
- [2] Adeyemi O, Owoseni M. Polyphenolic content and biochemical evaluation of fijik, alomo, osomo and oroki herbal mixtures in vitro. *Beni-Suef University Journal of Basic and Applied Sciences*. 2015; 4(3): 200-206.

- [3] Nili-Ahmadabadi A, Tavakoli F, Hasanzadeh G, Rahimi H, Sabzevari O. Protective effect of pretreatment with thymoquinone against Aflatoxin B1 induced liver toxicity in mice. *Daru: journal of Faculty of Pharmacy, Tehran University of Medical Sciences*. 2011; 19(4): 282.
- [4] Kashaw V, Nema AK, Agarwal A. Hepatoprotective prospective of herbal drugs and their vesicular carriers-a review. *International Journal of Research in Pharmaceutical and Biomedical Sciences*. 2011; 2(2): 360-374.
- [5] Oyewo EB. Sub-chronic Administration of Febi Super Bitters Triggered Inflammatory Responses in Male Wistar Rats. *Journal of Medical Sciences*. 2013; 13(8): 692-699.
- [6] Ekor M, Osonuga O, Odewabi A, Bakre A, Oritogun K. Toxicity evaluation of Yoyo 'cleanser' bitters and fields Swedish bitters herbal preparations following sub-chronic administration in rats. *American Journal of Pharmacology and Toxicology*. 2010; 5(4): 159-166.
- [7] Ogbonnia S, Mbaka G, Igbokwe N, Anyika E, Alli P, Nwakakwa N. Antimicrobial evaluation, acute and subchronic toxicity studies of Leone Bitters, a Nigerian polyherbal formulation, in rodents. *Agriculture and Biology Journal of North America*. 2010; 1(3): 366-376.
- [8] Oshodi O, Aina O. Paraga. Masked Alcohol' use and the associated socio-cultural factors among the Yoruba of south west Nigeria: a case study of secondary school students in Lagos. *Quarterly Journal of Mental Health*. 2007; 1(1).
- [9] Cosyns JP, Jadoul M, Squifflet JP, Wese FX, de Strihou CvY. Urothelial lesions in Chinese-herb nephropathy. *American journal of kidney diseases*. 1999; 33(6): 1011-1017.
- [10] Nandhakumar S, Parasuraman S, Shanmugam MM, Chand P, Bhat BV. Evaluation of DNA damage using single-cell gel electrophoresis (Comet Assay). *Journal of pharmacology and pharmacotherapy*. 2011; 2: 107-11.
- [11] Wu D and Cederbaum AI. Alcohol, oxidative stress, and free radical damage. *Alcohol Research & Health*. 2003 27(4): 277.
- [12] Urbano-Marquez A, Estruch R, Navarro-Lopez F, Grau JM, Mont L, Rubin E. The effects of alcoholism on skeletal and cardiac muscle. *New England Journal of Medicine*. 1989; 320(7): 409-415.
- [13] Corrao G, Bagnardi V, Zambon A, La Vecchia C. A meta-analysis of alcohol consumption and the risk of 15 diseases. *Preventive medicine*. 2004; 38(5): 613-619.
- [14] Heaton MB, Paiva M, Mayer J, Miller R. Ethanol-mediated generation of reactive oxygen species in developing rat cerebellum. *Neuroscience letters*. 2002; 334(2): 83-86.
- [15] Mocan T, Agoston-Coldea L, Rusu L, Pais R, Gatfosse M, Mocan L, Rusu M. The correlation between alcohol consumption, lipids, apolipoproteins and coronary heart disease. *Romanian journal of internal medicine*. 2008; 46(4): 2323.
- [16] George A, Figueredo VM. Alcohol and arrhythmias: a comprehensive review. *Journal of cardiovascular medicine*. 2010; 11(4): 221-228.
- [17] Quertemont E, Didone V. Role of acetaldehyde in mediating the pharmacological and behavioral effects of alcohol. *Alcohol Research & Health*. 2006; 29(4): 258-265.
- [18] Sato Y, Fujiwara H, Takatsu Y. Biochemical markers in heart failure. *Journal of cardiology*. 2012; 59(1): 1-7.
- [19] Édes I, Tószegi A, Csanady M, Bozóky B. Myocardial lipid peroxidation in rats after chronic alcohol ingestion and the effects of different antioxidants. *Cardiovascular research*. 1986; 20(7): 542-548.
- [20] McDonough KH. Antioxidant nutrients and alcohol. *Toxicology*. 2003; 189(1-2): 89-97.
- [21] Reinke L, Lai E, DuBose C, McCay P. Reactive free radical generation in vivo in heart and liver of ethanol-fed rats: correlation with radical formation in vitro. *Proceedings of the National Academy of Sciences*. 1987; 84(24): 9223-9227.
- [22] McCord JM. Free radicals and heart disease Nutritional impact of food processing. 1989; 43: 327-337.
- [23] Rajbanshi SL, Pandanaboina CS. Alcohol stress on cardiac tissue–Ameliorative effects of *Thespesia populnea* leaf extract. *Journal of cardiology*. 2014; 63(6): 449-459.
- [24] Adeyemi O, Akinwande O. Rat Plasma Metabolites and Renal Morphology Following Oral Exposure to a Polyherbal Mixture. *Research Journal of Medicinal Plant*. 2015; 9(1): 34-41.

- [25] Dawodu O, Ebuehi O, Odesanmi O, Olalekan M. Determination of Biochemical and Histological Parameters of Alcohol Administration in Wistar Rats. *Annual Research & Review in Biology*. 2019; 1-8.
- [26] Kasolo JN, Bimenya GS, Ojok L, Ogwal-Okeng JW. Sub-acute toxicity evaluation of *Moringa oleifera* leaves aqueous and ethanol extracts in Swiss Albino rats. *International Journal of Medicinal Plant Research*. 2012; 1(6): 075-081.
- [27] Kershaw CD and Guidot DM. Alcoholic lung disease. *Alcohol Res Health*. 2008;31(1): 66-75
- [28] Jones A. Measuring and reporting the concentration of acetaldehyde in human breath. *Alcohol and alcoholism*. 1995; 30(3): 271-285.
- [29] Qin G, Meng Z. The expressions of protooncogenes and CYP1A in lungs of rats exposed to sulfur dioxide and benzo (a) pyrene. *Regulatory Toxicology and Pharmacology*. 2006; 45(1): 36-43.
- [30] Lieber CS. Alcoholic fatty liver: its pathogenesis and mechanism of progression to inflammation and fibrosis. *Alcohol*. 2004; 34(1): 9-19.
- [31] Schumacher B, Hoeijmakers JH, Garinis GA. Sealing the gap between nuclear DNA damage and longevity. *Molecular and cellular endocrinology*. 2009; 299(1): 112-117.
- [32] Brooks PJ, Theruvathu JA. DNA adducts from acetaldehyde: implications for alcohol-related carcinogenesis. *Alcohol*. 2005; 35(3): 187-193.
- [33] Mechilli M, Schinoppi A, Kobos K, Natarajan AT, Palitti F. DNA repair deficiency and acetaldehyde-induced chromosomal alterations in CHO cells. *Mutagenesis*. 2008; 23(1): 51-56.
- [34] Saravanan R, Pugalendi K. Assessment of the pharmacological effect of silymarin on ethanol-induced DNA damage by single-cell gel electrophoresis. *Indian journal of pharmacology*. 2005; 37(4): 261.
- [35] Mutlu-Türkoğlu Ü, Doğru-Abbasoğlu S, Aykaç-Toker G, Mirsal H, Beyazyürek M, Uysal M. Increased lipid and protein oxidation and DNA damage in patients with chronic alcoholism. *Journal of Laboratory and Clinical Medicine*. 2000; 136(4): 287-291.

Author's Short Biography



Dr Eniola Bolawa is a Senior Lecturer in the University of Lagos, Nigeria and also an Environmental Toxicologist with a special focus on Environmental Toxicology and Nutritional Biochemistry. Her areas of specialization ranges from Environmental Health, Environmental Pollution, Heavy Metals in our environment and its impact on Health, Remediation of Pollution to Nutritional Biochemistry. She had both her undergraduate degree in 1994 from the University of Lagos and her Masters degree (1997). She bagged a doctorate degree in Environmental Biochemistry from the same Institute. She has over 15 years of experience in conducting research work in Environmental Toxicology. She has over 17 publications to her credit and was declared the best Course Adviser in Biochemistry department (2016/2017 session). She has supervised over 50 undergraduate students and also some postgraduate students.